

## UTERINE ANGIOMYOLIPOMA: A CASE REPORT, DIFFERENTIAL DIAGNOSIS WITH PECOMA AND REVIEW OF THE LITERATURE

**Tihomir P. Totev,**  
**Svetlana A. Mateva<sup>1</sup>,**  
**Margarita R. Nikolova<sup>1</sup>,**  
**Grigor A. Gorchev<sup>2</sup>**

*St. Marina Specialized Hospital  
of Obstetrics and Gynaecology –  
Pleven*

<sup>1</sup>*Department of General and  
Clinical Pathology, Medical  
University – Pleven*

<sup>2</sup>*Clinic of Oncogynaecology,  
University Hospital - Pleven*

### Summary

Angiomyolipomas are benign mesenchymal neoplasms, presenting with a variable mixture of adipose tissue, smooth muscle and vascular component. Although they are typically found in the kidneys, many cases of extrarenal angiomyolipomas have been reported. They are extremely rarely present in the uterus. We describe a case of a 56-year-old woman, operated on for leiomyoma. Total laparohysterectomy and bilateral adnexectomy was performed. After histological and immunohistochemical examination, the final diagnosis of uterine angiomyolipoma was made. Renal and extrarenal angiomyolipomas are compared in regard to clinical and morphological aspect and their difference from PEComas is discussed. PEComas have been defined during the last decade and there are still issues regarding terminological clarity and overlapping.

**Key words:** angiomyolipoma, PEComa, angiolipoleiomyoma

### Introduction

Angiomyolipomas (AML) are benign mesenchymal neoplasms that present a variable mixture of adipose and smooth muscle with a well-expressed vascular component. They are usually located in the kidneys. However, other extrarenal localizations have been reported [1, 2].

Most renal AMLs can be diagnosed preoperatively by computer tomography and ultrasound [2]. Because of the benign nature of the lesion, treatment, especially for small and asymptomatic tumours, is conservative. Surgical treatment is applied when the neoplasms are larger than 4 cm or complications with a rupture have occurred [3]. Renal AMLs can be sporadic or combined with tuberous sclerosis (TS) – a hereditary autosomal dominant complex, presenting with multiple hamartomas in various internal organs [1, 2, 3]. In both cases, renal AMLs express melanocytic and smooth-muscle markers [1, 2]. The clinical presentation of uterine AMLs is variable, often similar to that of typical leiomyomas (LM) – menometrorrhagia, presence of pelvic mass, abdominal pain or even lack of symptoms [4, 5].

### Corresponding Author:

Tihomir P. Totev  
e-mail: t.totev@mail.bg

**Received:** April 04, 2014

**Revision received:** July 10, 2014

**Accepted:** November 24, 2014

Sonography does not distinguish AMLs from uterine LMs but endovaginal sonography, combined with CT and MRI allows a more detailed preoperative diagnosis [4]. In most cases AMLs originate from the uterine body but cases have been reported of cervical localization [6], mostly in females over 40 [7]. They vary in size (2-16 cm) and are well-wrapped in a pseudocapsule [8]. Uterine AMLs are benign, and progression to malignancy has not been reported [9].

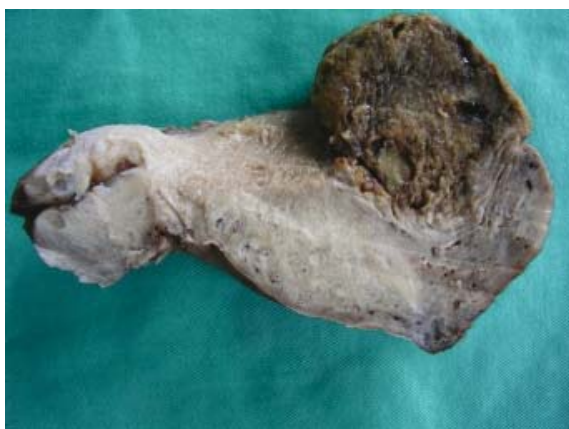### Case report

A 56-year-old patient presented with low abdominal pain. The gynaecological examination revealed a myomatous node on the anterior uterine wall. The patient underwent total laparohysterectomy and bilateral adnexectomy. The node was located in the submucosa of the anterior uterine wall. Macroscopically, it was soft, round, yellowish, 6 cm in diameter, with clearly-cut boundaries (Fig. 1). The adnexa had age-related alterations and inclusion cysts.

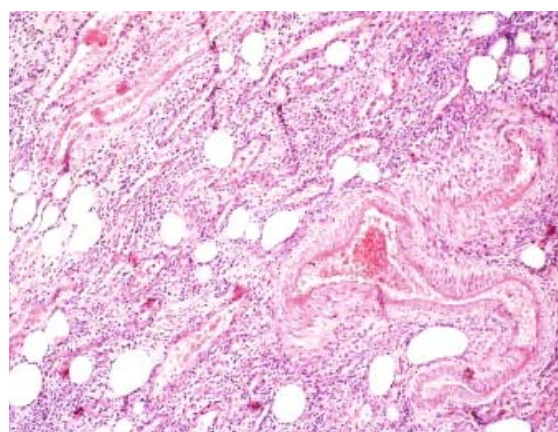
Histology of the tumor proved three tissue components: smooth muscle fibers, mature adipose tissue and multiple thick-walled vessels (Fig. 2).

No mitoses, atypical cell structures or necrotic changes were found. The smooth muscle component was immunoreactive to  $\alpha$ -SMA (Fig. 3). Based on macroscopic, histological and immunohistological findings, the final diagnosis was AML, after ruling out PEComa.

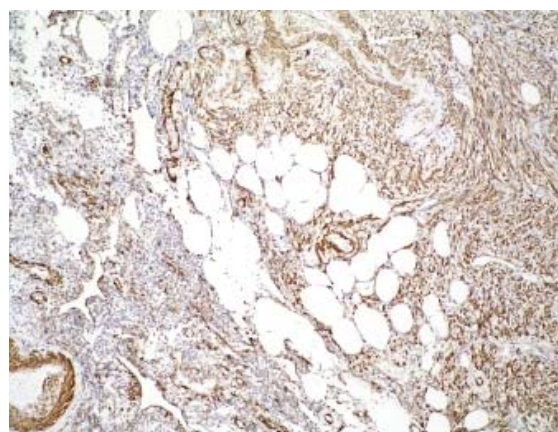
Following uneventful recovery, the patient was discharged on the 6<sup>th</sup> postoperative day.



**Figure 1.** Macroscopically, the tumor is round, well-delimited, soft and yellowish, 6 cm in diameter, located submucosally on the anterior uterine wall.



**Figure 2.** Histologically, the tumor is composed of three tissue components: smooth muscle fibers, mature adipose tissue and multiple thick-walled vessels. (H&E stain, 250 x)



**Figure 3.** Smooth muscle component was immunoreactive to  $\alpha$ -SMA (250 x)

### Discussion

Intrauterine AMLs are extremely rare, and are not officially listed in the WHO Classification of female reproductive system tumors [11]. When these are of intrauterine localization, they are reported as AMLs [1, 8-15], angiolipoleiomyomas (ALLM) [4, 7, 16, 17] or lipoleiomyomas with abnormal vessels [18]. They all present the same type of lesion, consisting of fatty tissue, smooth muscle and a well-expressed vascular component. There is no exact definition of the so-called “vascular component”. It usually includes descriptions of arteries as abnormal, small- to medium-sized, with varying thickness of the walls and a well-developed capillary network [7]. In the literature available,

intrauterine tumors with such features were first referred to as ALLM in a report by Sieinski in 1989 [17]. Since then, 17 cases of AMLs have

been reported, including this one. These are presented on Table 1.

**Table 1.** Cases of AMLs reported in the literature

No	Reference	Age of patient	Tumor/HMB45 reactivity
1	[18] Sieinski 1989	52	ALLM/ not analyzed
2		52	ALLM/ not analyzed
3		57	ALLM/ not analyzed
4	[14] Laffargue et al. 1993	20	AML/ HMB 45-
5	[19] Shintaku 1996	67	lipoleiomyoma with abnormal arterial vessels/ not analyzed
6	[7] Huang et al. 2000	34	ALM/ HMB 45-
7	[12] Chetty et al. 2000	52	ALM/ not analyzed
8	[9] Yaegashi et al. 2001	40	ALM/ HMB 45-
9	[4] Braun et al. 2002	51	ALLM/ not analyzed
10	[6] Heidi et al. 2002	?	ALM/ not analyzed
11	[8] Ren et al. 2004	40	ALLM/ HMB 45-
12	[13] Cil et al. 2004	32	ALM/ HMB 45+
13	[10] Cho et al. 2009	62	ALM/ HMB 45-
14	[17] Kajo et al. 2010	53	ALLM/ HMB 45-
15	[16] Ylmaz et al. 2013	44	ALM/ HMB 45-
16	[15] Lee et al. 2013	41	ALM/ not analyzed
17	Case presented 2014	56	AMJI/ HMB 45-

Apart from differences in the clinical presentation, other differences between renal and extrarenal AMLs have been found that can be useful in making the differential diagnosis. For example, renal and hepatic AMLs combine with tuberous sclerosis (TS) in 5-50% of the cases. However, this combination is not seen in the rest of extrarenal tumors [6]. Of the 17 cases of extrarenal tumors, shown on Table 1, a combination with TS was reported in only two patients [12, 14].

Immunoreactivity to HMB-45 has been reported for tumors of the colon, parametria and lymph nodes but it is not typical of uterine AMLs [6-8]. One of the 17 above mentioned cases of uterine AMLs was reported to be immunoreactive to HMB-45, and the remainder were not investigated [12]. The smooth muscle cells in the renal and hepatic tumors are epithelioid, whereas in the AMLs these cells are elongated.

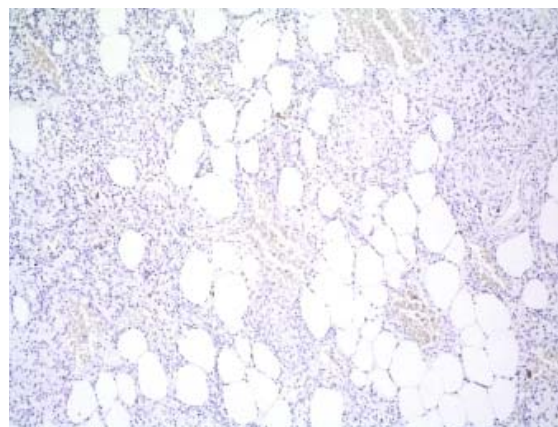
Epithelioid AMLs (the term PEComas seems to be more appropriate, see below) are potentially malignant mesenchymal neoplasms, characterized mainly by proliferation of epithelioid cells. These cells are immunoreactive

to melanocytic markers and are a monophasic smooth muscle formation of a common triphasic neoplasm [19-21]. In more than 50% of the cases they are combined with TS. Most patients are symptomatic since the tumors are usually large and infiltrative [19].

During the last decade a family of tumors has been fully differentiated. They derive from perivascular epithelioid cells (PEC). These cells express both myogenic and melanocytic markers. The expression includes some forms of AMLs and lymphangioliomyomatosis (LAM) as well as clear-cell “sugar” lung tumor, clear-cell myomelanocytic tumor of the falciform ligament and rare atypical tumors of other anatomical localizations [21-23]. The term PEComa was proposed by Zamboni in 1996 [23].

Most often, these tumors are located in the uterus and the retroperitoneal space [24]. The first intrauterine PEComa was described by Pea M. et al. in 1996 [25]. At present, nearly 50 cases of intrauterine PEComas have been reported, most of them described during the last decade. These cases include tumors, designated

as PEComas, perivascular epithelioid cell tumours, abdominopelvic sarcomas, mesenchymal neoplasms with HMB-positive epithelioid cells or 5 epithelioid AMLs [25-46]. The clinical symptoms are non-specific and variable, and the ultrasound image depends on the biological features of the tumour. Therefore, neither the clinical presentation nor the ultrasound findings are sufficient to make a preoperative diagnosis. Association with TS has been established in about 9% of the cases. In the largest group of 44 uterine PEComas investigated, 37 tumours were clinically followed up and 16 were proved as clinically aggressive [47]. In 2005, Folpe et al. proposed morphological criteria, including infiltrative growth, tumour size, nucleic polymorphism, cellularity, mitotic activity, necrosis and vascular invasion. According to these criteria, PEComas, irrespective of their localizations, have been classified as either benign, as such with uncertain malignant potential, or as malignant [34]. Applying the same morphological markers, other authors classify uterine PEComas as malignant or non-malignant [47]. These morphological markers have been used for too short to determine their reliability. In addition, the low incidence of PEComas makes the therapeutic approach to such cases difficult to specify. However, because of the unpredictable behaviour of the neoplasms in this group, some authors find it appropriate to plan for a long period of follow-up [21, 34, 46, 47]. Therefore, there exists a great variety of diversity of terms used to designate tumors belonging to one and the same pathomorphological group. On the other hand, the terms for morphologically different neoplasm overlap. All these practices result in a certain terminological confusion and make it difficult to choose an exact term for each tumor. This poses a serious problem, insofar as PEComas are neoplasms of uncertain malignant potential and their diagnosing is crucial. Moreover, because these neoplasms are likely to be combined with TS, patients need to have other internal organs investigated. For this purpose, it is very important to use the term PEComa for tumors, composed of only, or predominantly of epithelioid HMB-45+ cells [20, 46, 47]. Therefore, an epithelioid AML is in fact a kind of PEComa [46]. To avoid overlooking /omissions in diagnosing PEComas, all uterine mesenchymal tumors with predominantly epithelioid appearance should be tested with melanocytic markers or at least with HMB-45 [46, 47].



**Figure 4.** All the tissue components are negative to HMB-45 (250 x)

## Conclusion

We believe that in the near future, with a sufficient number of cases registered, the issues concerning terminological problems, morphological criteria and therapeutic approach to PEComas will find their final solution.

## References

1. Huang PC, Chen JT, Ho WL. Clinicopathologic analysis of renal and extrarenal angiomyolipomas: report of 44 cases. *Chinese Med J.* 2000;63(1):37-44.
2. Martignoni G, Amin MB. Angiomyolipoma. In: Fletcher CDM, Unni KK, Mertens F, editors. *World Health organization classification of tumors: pathology and genetics of tumors of urinary system and male genital organs.* Lyon: IARC Press; 2003. p. 65-7.
3. Kwok P. Interventional radiological treatment of renal angiomyolipoma. *Medical Bulletin.* 2010;15(7):15-16.
4. Braun HL, Wheelock JB, Amaker BH, Seeds JW. Sonographic evaluation of a uterine angiomyolipoma. *J Clin Ultrasound.* 2002;30(4):241-4.
5. Demopoulos RJ, Denarvaez F, Kaji V. Benign mixed mesodermal tumors of the uterus: a histogenetic study. *Am J. Clin. Pathol.* 1973, 60(3):377-83.
6. Huang PC, Chen JT, Ho WL. Clinicopathologic analysis of renal and extrarenal angiomyolipomas: report of 44 cases. *Chinese Med J.* 2000;63(1):37-44.
7. Ren R, Wu HH. Pathologic quiz case a 40-year-old

- woman with an unusual uterine tumor. *Arch Pathol Lab Med.* 2004; 128:e31-32
8. Yaegashi H, Moriya T, Soeda S, Yonemoto Y, Nagura H, Sasano H. Uterine angiomyolipoma: case report and review of the literature. *Pathol Int.* 2001;51(11):896-901.
  9. Cho H, Kim H, Lee M, Kim KK. Uterine angiomyolipoma with partial cystic changes. *J Womens Med.* 2009;2(2):88-91.
  10. Tavassoli F A, Devilee P. Pathology and genetics of tumours of the breast and female genital organs. In: Fletcher CDM, Unni KK, Mertens F, editors. *World Health organization classification of tumors: pathology and genetics of tumors of urinary system and male genital organs.* Lyon: IARC Press; 2003. p. 114-289.
  11. Chetty R, Pillay P. Sporadic Angiomyolipoma of the uterus. *J Gynecol Surg.* 2000;16(2):87-91.
  12. Cil AP, Haberal A, Hucumenoglu S, Kovalak EE, Gunes M. Angiomyolipoma of the uterus associated with tuberous sclerosis: case report and review of the literature. *Gynecol Oncol* 2004;94(2):593-6.
  13. Laffargue F, Giacalone PL, Charpin C, Lachard A. Uterine angiomyolipoma associated with pregnancy. *Gynecol Oncol.* 1993;50:357-60.
  14. Lee SJ, Yoo JY, Yoo SH, Seo YH, Yoon JH. Uterine angiomyolipoma with metastasis in a woman with tuberous sclerosis: a case report. *Eur J Gynaecol Oncol.* 2013;34(4):339-342.
  15. Yilmaz M, Ingec M, Isaoglu U, Sipal S. Angiomyolipoma of the uterus. *Eur J Gen Med.* 2013;10(3):178-180.
  16. Kajo K, Žúbor P, Krivuš Š. Danko J. Angiolipoleiomyoma of the uterus. Case report and literature review. *Ceska Gynekol.* 2010;75(1):54-6.
  17. Sieinski W. Lipomatous neometaplasia of the uterus: report of 11 cases with discussion of histogenesis and pathogenesis. *Int J Gynecol Pathol.* 1989;8(4):357-63.
  18. Shintaku M. Lipoleiomyomatous tumors of the uterus: a heterogeneous group? Histopathological study of five cases. *Pathol Int.* 1996;46(7):498-502.
  19. Amin MB. Epithelioid angiomyolipoma. In: Fletcher CDM, Unni KK, Mertens F, editors. *World Health organization classification of tumors: pathology and genetics of tumors of urinary system and male genital organs.* Lyon: IARC Press; 2003. p. 68-9.
  20. Bonetti F, Pea M, Martignoni G, Manfrin E, Gambacorta M, Faleri M, et al. The perivascular epithelioid cell and related lesions. *Adv Anat Pathol.* 1997;4(3):343-358.
  21. Martignoni G, Pea M, Reghellin D, Zamboni G, Bonetti F: PEComas: the past, the present and the future. *Virchows Arch.* 2008;452(2):119-32.
  22. Folpe AL. Neoplasms with perivascular epithelioid cell differentiation (PEComas). In: Fletcher CDM, Unni KK, Mertens F, editors. *World Health organization classification of tumors: pathology and genetics of tumors of urinary system and male genital organs.* Lyon: IARC Press; 2003. p. 221-2.
  23. Hornick JL, Fletcher CDM. Pecoma: what do we know so far? *Histopathology.* 2006;48(1):75-82.
  24. Zamboni G, Pea M, Martignoni G, Zancanaro C, Faccioli G, Gilioli E, et al. Clear cell "sugar" tumor of the pancreas. A novel member of the family of lesions characterised by the presence of perivascular epithelioid cells. *Am J Surg Pathol.* 1996;20(6):722-30.
  25. Armah HB, Parwani AV. Perivascular epithelioid cell tumor. *Arch Pathol Lab Med.* 2009;133(4):648-54.
  26. Armah HB, Parwani AV. Malignant perivascular epithelioid cell tumor (PEComa) of the uterus with late renal and pulmonary metastases: a case report with review of the literature. *Diagn Pathol.* 2007;2:45. doi:10.1186/1746-1596-2-45.
  27. Azad NS, Aziz AB, Pervez S, Kayani N. Uterine perivascular epithelioid cell tumour presenting as a cervical mass. *J Pak Med Assoc* 2006;56(2):83-4.
  28. Bernardo Vega R, Camino FV, Fernandez MDC, Segura GQ, Gonzalez JM, Gonzalez-Tejero C. The PEComa Tumor: Could it be considered an independent neoplastic entity. *J Gynecol Surg.* 2005;21:161-6.
  29. Bonetti F, Martignoni G, Colato, Manfrin E, Gambacorta M, Faleri M, et al. Abdominopelvic sarcoma of perivascular epithelioid cells: report of four cases in young women, one with tuberous sclerosis. *Mod Pathol.* 2001;14(6):563-8.
  30. Bosincu L, Rocca PC, Martignoni G, Nogales FF, Longa L, Maccioni A, Massarelli G. Perivascular epithelioid cell (PEC) tumors of the uterus: a clinicopathologic study of two cases with aggressive features. *Mod Pathol.* 2005;18:1336-42.
  31. D'Andrea V, Lippolis G, Biancari F, Ruco LP, Marzullo A, Wedard BM, et al. A uterine pecoma: a case report. *G Chir.* 1999;20(4):163-4.
  32. Dimmler A, Seitz G, Hohenberger W, Kirchner T, Faller G. Late pulmonary metastasis in uterine PEComa. *J Clin Pathol* 2003;56(8):627-8.
  33. Fadare O, Parkash V, Yilmaz, Mariappan MR, Ma L, Hileeto D, et al. Perivascular epithelioid cell tumor (PEComa) of the uterine cervix associated with intraabdominal "PEComatosis": A clinicopathological study with comparative genomic hybridization analysis. *World J Surg Oncol.* 2004;2:35.
  34. Folpe AL, Mentzel T, Lehr HA, Fisher C, Balzer BL, Weiss SW. Perivascular epithelioid cell neoplasms of soft tissue and gynecologic origin: a clinicopathologic study of 26 cases and review of the literature. *Am J Surg Pathol.* 2005;29(12):1558-75.
  35. Fukunaga M. Perivascular epithelioid cell tumor

- of the uterus: report of four cases. *Int J Gynecol Pathol.* 2005;24(4):341-6.
36. Fukunaga M. Perivascular epithelioid cell tumor of the uterus: a case report. *Int J Gynecol Pathol.* 2004;23:287-91.
  37. Gan MF, Yu CK, Jin M, Lu HS, Li HM. Perivascular epithelioid cell tumor of the uterus: report of three cases. *Chin Med J.* 2007;120(6):526-8.
  38. Gao Z, Bhuiya T, Anderson A. Perivascular epithelioid cell tumour (PEComa) of the uterus associated with malignant neoplasm of the female genital tract. *J Obstet Gynaecol.* 2004;24(5):600-4.
  39. Greene LA, Mount SL, Schned AR, Cooper K. Recurrent perivascular epithelioid cell tumor of the uterus (PEComa): an immunohistochemical study and review of the literature. *Gynecol Oncol.* 2003;90(3):677-81.
  40. Iravanlo G., Nozarian Z. Uterine perivascular epithelioid cell tumor: a case report. *Acta Medica Iranica.* 2006;44(1):63-4.
  41. Jeon IS, Lee SM. Multimodal treatment using surgery, radiotherapy, and chemotherapy in a patient with a perivascular epithelioid cell tumor of the uterus. *J Pediatr Hematol Oncol.* 2005;27(12):681-4.
  42. Liang SX, Pearl M, Liu J, Hwang S, Tornos C. "Malignant" uterine perivascular epithelioid cell tumor, pelvic lymph node lymph-angioliomyomatosis, and gynecological pecomatosis in a patient with tuberous sclerosis: a case report and review of the literature. *Int J Gynecol Pathol* 2008;27(1):86-90.
  43. Nikolova M, Natchev R, Gortchev G. HMB-45-positive perivascular epithelioid cell tumor ("PEComa") of the uterus. *Clin Applic Immun.* 2004;3(2):397-399.
  44. Park SH, Ro JY, Kim HS, Lee ES. Perivascular epithelioid cell tumor of the uterus: immunohistochemical, ultrastructural and molecular study. *Pathol Int.* 2003;53(11):800-5.
  45. Rammeh Rommani S, Trabelsi A, Attia L, Msakni I, Koubaa A, Ben Jilani S, et al. Perivascular epithelioid cell tumor of the uterus: a case report. *Pathologica.* 2006;98(6):649-51.
  46. Vang R, Kempson RL. Perivascular epithelioid cell tumor ('PEComa') of the uterus: a subset of HMB-45-positive epithelioid mesenchymal neoplasms with an uncertain relationship to pure smooth muscle tumors. *Am J Surg Pathol.* 2002;26(91):1-13.
  47. Fadare O. Uterine PEComa: appraisal of a controversial and increasingly reported mesenchymal neoplasm. *Int Semin Surg Oncol* 2008;5:7. doi:10.1186/1477-7800-5-7.