

EMBRYOLOGICAL ASPECTS AND ANATOMICAL VARIATIONS OF THE INFERIOR VENA CAVA – ITS IMPORTANCE IN GYNECOLOGIC ONCOLOGY SURGERY

Stoyan G. Kostov
Nadezhda H. Hinkova¹
Svetla E. Dineva^{2,3}
Angel D. Yordanov⁴

*Department of Gynaecology,
 Saint Anna University Hospital,
 Medical University – Varna*
¹*Medical University Pleven,
 University Hospital Saint Marina –
 Pleven, Bulgaria*

²*Diagnostic Imaging Department,
 Medical University – Sofia*

³*National Cardiology Hospital – Sofia*

⁴*Department of Gynecologic Oncology,
 Medical University – Pleven, Bulgaria*

Corresponding Author:

*Angel D. Yordanov
 Department of Gynecologic Oncology,
 Medical University Pleven
 1 Kliment Ohridski Str.,
 Pleven, 5800
 Bulgaria
 e-mail: angel.jordanov@gmail.com*

Received: February 13, 2022

Revision received: March 08, 2022

Accepted: May 11, 2022

Summary

Surgical procedures of the retroperitoneum are often performed in gynecologic oncology surgery clinics. The most complex among them is paraaortic lymphadenectomy. It is generally performed in cases of bulky lymph nodes in ovarian carcinomas and sarcomas to achieve optimal cytoreduction. In the early stages of ovarian cancer, type II non-endometrioid endometrial cancer, and in advanced stages of cervical cancer, paraaortic lymphadenectomy is an integral part of staging. Moreover, the retroperitoneum is approached in cases of retroperitoneal gynecologic sarcomas. The largest vessels of the human body – the inferior vena cava and the abdominal aorta are localized in the retroperitoneum. Therefore, iatrogenic vessel injury during oncogynecological surgery is more likely to affect the inferior vena cava. Anatomical variations of the vein additionally increase the risk of vascular lesions. Therefore, surgeons should be aware of possible anatomical variations. The present article aimed to highlight the heterogeneity of anatomical variations of the inferior vena cava related to gynecologic oncology surgery. Embryogenesis of the vein and its variations are also discussed. Additionally, some anomalies of the ureter, associated with the embryogenesis of the inferior vena cava, are mentioned.

Keywords: inferior vena cava, embryological aspects, anatomical variations, gynecologic oncology surgery

Introduction

The inferior vena cava (IVC) is derived by the convergence of both common iliac veins (CIVs) at the level of the 5th lumbar vertebra. It leaves the abdomen by piercing the diaphragmatic central tendon at the caval opening at the level of the eighth thoracic vertebra [1]. Generally, the IVC is a single and right-sided vessel formed by four pairs of veins in the embryo. It is posterior to the duodenum, vena portae, and liver [2]. It is the largest vessel that drains blood from the pelvis and lower limbs [3]. Variations

of the IVC are rare but essential entities, which radiologists and surgeons must suspect as they can be of substantial clinical importance. A radiologist should differentiate an anomalous IVC or a possible pathologic process such as lymphadenopathy [4]. Injury of unrecognized anomalous IVC may have catastrophic consequences for a patient.

Moreover, such vein variations increase morbidity and mortality during surgery. Therefore, surgeons should be familiar with and aware of possible IVC variations to avoid intraoperative vessel laceration during surgical procedures. The present article emphasizes the heterogeneity of anomalous IVC, which is related to gynecologic oncology surgery. Embryogenesis of the vein anatomy is also discussed. Additionally, some anomalies of the ureter, associated with the embryogenesis of the inferior vena cava, are discussed.

Embryogenesis of the IVC

The IVC forms during the sixth to tenth gestation week through a complex process of subsequent regression and extensive anastomotic development of channels among the vitelline, posterior cardinal (PCVs), subcardinal (SUVs), and supracardinal veins (SUPVs) [4, 5]. These

veins develop in a sequence [6]. Vitelline veins develop in the 4th week of embryogenesis. These vessels drain the blood from the yolk sac. The second to form are the PCVs. They are located at the posterior aspect of the fetus and drain the blood from the inferior part of the embryo to the common cardinal vein.

Consequently, these vessels completely regress besides their caudal parts, which become the iliac bifurcation and iliac veins. Cranially, the sinusoidal network is derived from the umbilical and vitelline veins (VIVs). As later the umbilical veins regress, the superior part of the VIVs forms the paired hepatocardiac channels. The left hepatocardiac channel regresses, whereas the right persists and forms the hepatic compartment of the IVC [4, 5, 7]. The SUVs are paired veins, which emerge in the seventh week of gestations. They are medial and parallel to the posterior cardinal veins. The SUPVs, which predominate in week 8 of gestation, are located medial to the regressed PVCs and lateral to the SUVs. These veins later extend beyond the diaphragm and become azygos and hemiazygos veins. Extensive anastomoses emerge between paired SUVs and between SUVs and SUPVs. The left subcardinal vein (SUV) completely regresses, whereas the right SUV creates the suprarenal part of the IVC and unites the developing hepatic IVC. Similar

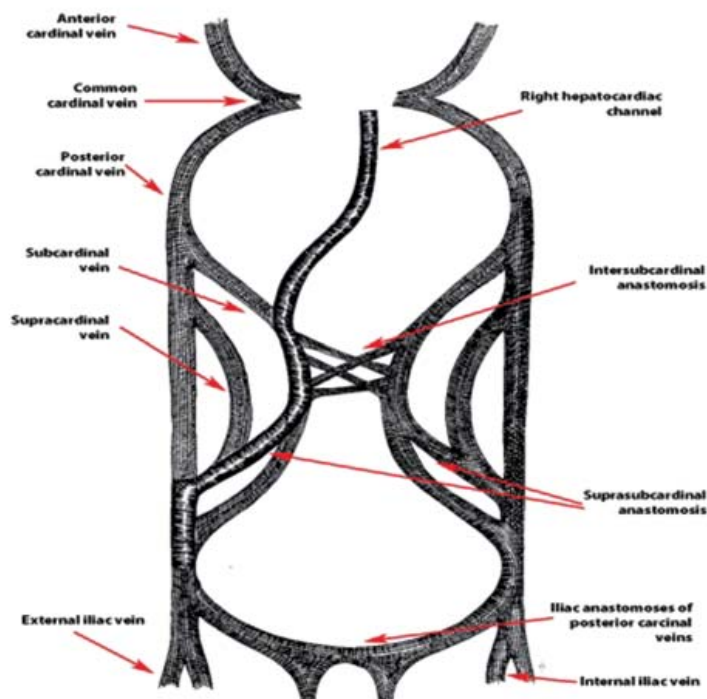


Figure 1. Embryogenesis of the IVC

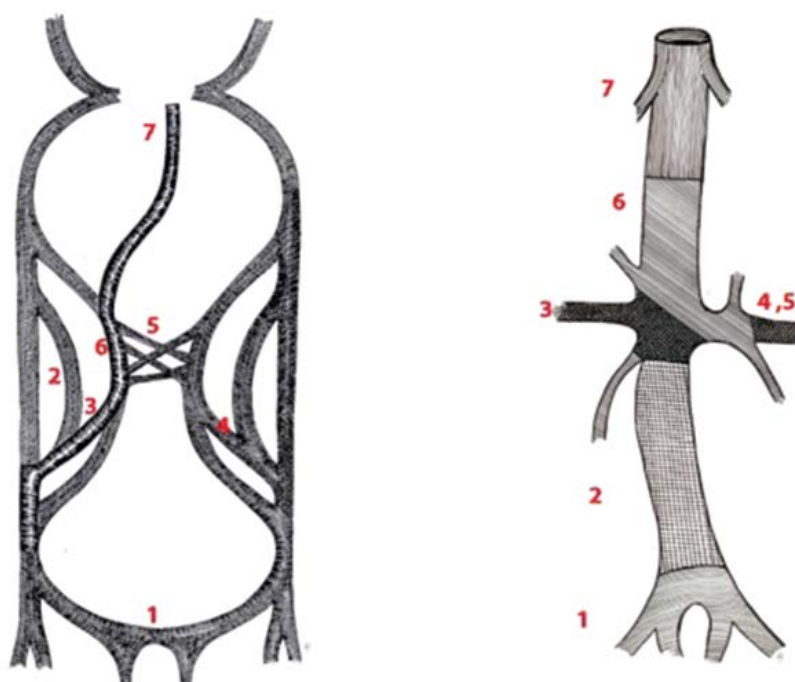


Figure 2. Embryogenic steps of the development of the IVC. A – Embryology of the IVC. B – Definitive IVC. 1 – Confluence of the CIVs, external and internal iliac veins. 2 - Right SUPV forms the infrarenal segments of the IVC. 3 – Right suprasubcardinal anastomoses form the right renal vein. 4, 5 - Left suprasubcardinal anastomoses and intersubcardinal anastomoses form the left renal vein. 6 - Right SUV forms the suprarenal segment of the IVC. 7 - VIVs form the hepatic segment of the IVC

to SUVs veins, the left supracardinal vein (SUPV) regresses, and the right one becomes the infrarenal part of the IVC. The right renal vein is formed by right suprasubcardinal anastomosis, whereas the left renal vein is derived from the left suprasubcardinal and intersubcardinal anastomoses. As a result, the definitive IVC is composed of four segments: hepatic (VIVs), suprarenal (right SUV), renal (right suprasubcardinal and left suprasubcardinal and intersubcardinal anastomoses), and infrarenal segment (right SUPV) [4-8] (Figure 1,2).

Paraaortic lymph nodes (PALNs)

The risk of injury to the IVC is increased during surgery of the retroperitoneum in gynecologic oncology. The risk is higher, especially during PALNs dissection. Therefore, PALNs in the paraaortic region will be described.

PALNs are divided into paraaortic (lateroaortic, preaortic and retroaortic), aortocaval and paracaval (precausal, laterocaval and retrocaval) [1].

The topographic anatomy of PALNs is shown in Figure 3.

IVC congenital anomalies

Generally, the following subtypes of the IVC are delineated in the present article [9]:

1. Left
2. Ipsilateral duplication
3. Bilateral duplication
4. Bilateral duplication with regressed right IVC
5. Marsupial
6. Retrocaval/circumcaval ureter
7. Congenital absence

Left IVC

Prevalence and surgical anatomy

A left IVC arises through abnormal regression of the right SUPV with persistence of the left SUPV [8]. The presence of left IVC accounts for 0.3% of variations, with a 95% confidence interval between 0.2% and 0.5% [10]. It is the second most common IVC variation after its bilateral duplication [11]. There are two subtypes – in the first type, the left IVC anteriorly crosses the abdominal aorta (AA) at the level of the left renal vein and continues as the right-sided IVC. In contrast, the left IVC does not cross the AA

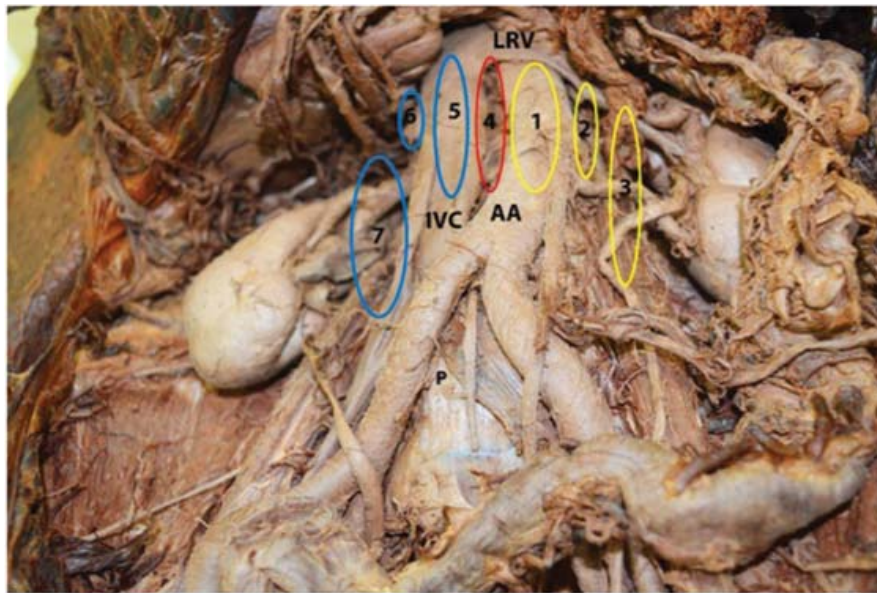


Figure 3. Paraaortic lymph nodes. 1 – preaortic lymph nodes. 2 - retroaortic lymph nodes. 3 - lateroaortic lymph nodes. 4 – aortocaval lymph nodes. 5 – precaval lymph nodes. 6 – retroaortic lymph nodes. 7 - laterocaval lymph nodes. AA – abdominal aorta, IVC – inferior vena cava, LRV – left renal vein, P – promontory

in the second type and continues its passage upward [11]. The left-sided IVC is a mirror image of the normal right-sided inferior vena cava – the left ovarian vein drains into the left IVC, and the right ovarian vein drains into the IVC [4]. Although it is a rare variation, many case reports describe it [12-14]. Chang et al. reported a case of left IVC in a woman who underwent an operation for endometrial cancer. A radiologist missed the anomaly, although

preoperative magnetic resonance imaging (MRI) was performed [13]. Though most cases with left IVC are asymptomatic, there are cases with venous thrombosis and pulmonary embolism related to this variation [15, 16]. Left IVC is shown in Figure 4.

Tips and tricks

Oncogynecologists must be aware of such anomalous vessels during aortocaval,

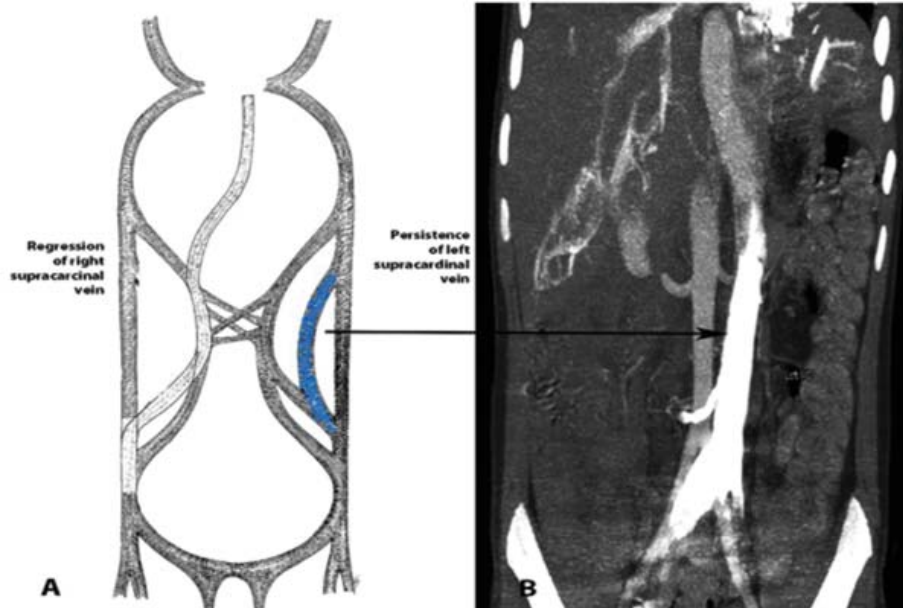


Figure 4. Left IVC. A – Embryonic etiology of the left IVC. B - abdominal CT in the coronal plane. The contrast-enhanced left vena cava is positioned on the left side

para-aortic lymph nodes dissection and perform a meticulous dissection to avoid vessel laceration [13]. The left IVC should be diagnosed preoperatively by imaging modalities. Still, the surgeon must remember that it could be misdiagnosed with cancer metastases, lymphadenopathy, retroperitoneal cyst, dilated ureter, or ovarian vein during radiological investigations [13, 14]. Moreover, one should bear in mind that left IVC is often accompanied by other vascular anomalies such as additional renal veins, ovarian vein anomalies, or ipsilateral IVC duplication [11-15].

Ipsilateral duplication of the IVC

Prevalence and surgical anatomy

Ipsilateral duplication of the IVC could be encountered on both sides of the AA – left-sided duplication and right-sided duplication of the IVC. Moreover, variations involving CIVs are often related to ipsilateral duplication of the IVC [17-19]. Doyle et al. were the first to describe ipsilateral (right-sided) duplication of the IVC. The ureter was located lateral to both venous channels. Therefore, this finding excluded the persistence of the right postcardinal vein [19]. Embryologically, it seems logical that the right-sided duplication of the IVC is derived from the right SUPV and the SUV vein [19]. Tagliafico et al. reported a right-sided duplication of the IVC – dorsal and ventral vein: the gonadal vein drained into the ventral vein [18]. Dumitru et al. reported

a case of left-sided duplication of the inferior vena cava in a patient with sigmoid colon cancer. The authors concluded that as potentially life-threatening surgical complications might occur, a preoperative diagnosis of such an anatomical variation is of utmost importance [17].

Tips and tricks

Oncogynecologists should be aware of the variations described above to avoid catastrophic vessel injury. Attention should be paid during para-aortic and paracaval lymph node dissection.

Bilateral duplication of the IVC

Prevalence and surgical anatomy

The bilateral duplication of the IVC (BDIVC) results from the persistence of the left and right SUPVs. Because of the close relationship between the ovarian and the IVC in embryogenesis, variations of both vessels are common findings [3]. Hostiuc et al. estimated that the prevalence of BDIVC was 0.7%, with a 95% confidence interval between 0.5% and 0.9% [10]. According to other authors, the incidence varies between 0.2%-3% [8, 9]. Generally, the left IVC typically drains into the left renal vein (LRV), and both vessels have a pre-aortic course [8, 9]. However, the LRV and the left IVC could have a retro-aortic course [20]. Usually, the right IVC is the dominant vessel with a larger caliber than its left counterpart [20]. Concurrent anomalies of the renal veins are often encountered

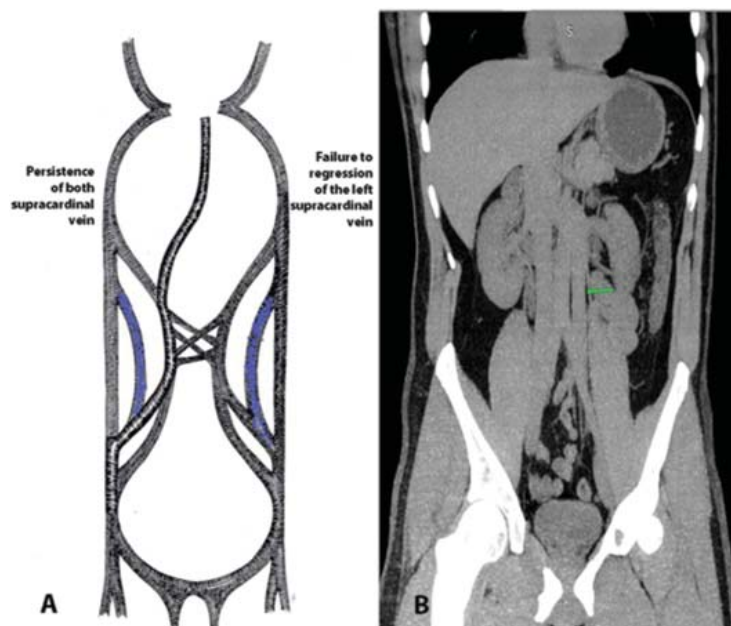


Figure 5. BDIVC. A – embryonic etiology of the BDIVC. B – Abdominal CT in the coronal plane of the BDIVC

– retroaortic left renal vein or circum-aortic renal vein known as a ‘venous collar’ [20- 26]. Moreover, in some cases, anastomoses between right and left CIVs at the caudal origin of the BDIVC could be noticed [5, 21]. Worldwide, many case reports describe the association of the BDIVC with venous thrombosis, recurrence of pulmonary thromboembolism, retrocaval ureters, and kidney anomalies [22-28]. BDIVC is shown in Figure 5.

Tips and tricks

Retroperitoneal paraaortic lymph node dissection is an integral part of treating patients with gynecologic carcinomas [29]. This procedure is associated with a higher complications rate in patients with normal anatomy. The bilateral duplication of the IVC is associated with an even much higher possibility of vessel injury during paracaval and paraaortic lymph node dissection. In addition, iliac anastomoses between both iliac vessels could be injured during aortocaval lymph node dissection; therefore, surgeons should be aware of such variations to reduce surgical risk. Moreover, every patient should undergo radiological examinations by computed tomography (CT) or MRI before paraaortic lymph node dissection [29, 30]. However, it

must be pointed out that such a variation could be misdiagnosed radiologically as a saccular aortic aneurysm, lymphadenopathy, ureteric dilatation, tumours of the retroperitoneum, loops of the small bowel, and misdiagnosing could lead to unnecessary interventions and morbidity [15, 30, 31].

Bilateral duplication of the IVC with regressed right IVC

Prevalence and surgical anatomy

Bilateral duplication of the IVC with regressed right IVC is an extremely rare variation. Only a few cases have been described in the medical literature [32, 33]. Homma et al. reported a case of left IVC with regressed right IVC, which received numerous venous tributaries. At the level of the third lumbar vertebral body, the left IVC turned obliquely to the right and crossed superficially to the AA [32]. Taniguchi et al. described a case of a dominant left-sided IVC and a hypoplastic right IVC. During inferior venocavography, the flow from the lower portion of the right IVC drained into the upper portion through collateral veins [33]. Both common iliac veins drained into the left IVC, which drained into the left renal vein [33]. This anomaly is shown in Figure 6.

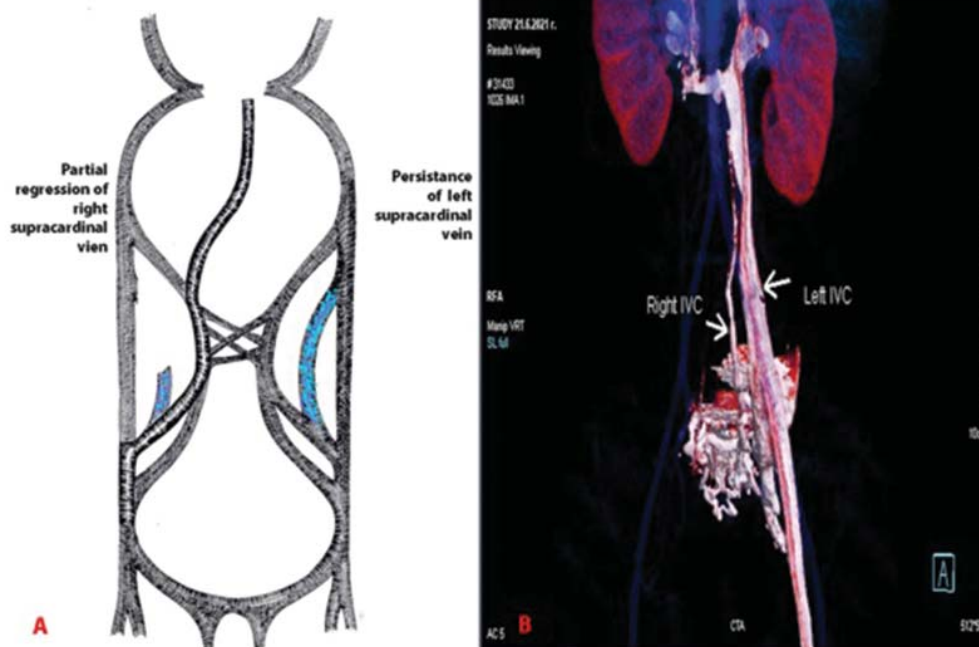


Figure 6. Left IVC with regressed right IVC. A - embryonic etiology of the left IVC with regressed right IVC. B - 3D volume rendered reconstruction in coronal view. Right-sided IVC is regressed with multiple presacral venous communications between both caval systems

Tips and tricks

Oncogynecologists should be careful during lateroaortic and retroaortic lymph node dissection. Additionally, the right regressed IVC could be injured during right latero- and retrocaval lymph node dissection. Moreover, aortocaval dissection increases the risk of venous injury in cases of vein anastomoses between both caval vessels.

Marsupial IVC

Prevalence and surgical anatomy

Marsupial IVC is a rare vessel variation in which the confluence of the common iliac veins (CIV) or IVC is located anterior to the right common iliac artery or the bifurcation of the AA. This anomaly is also termed “preaortic iliac venous confluence”. Embryologically, it results from persistence of the superior compartment of the circumaortic venous ring, associated with regression of the posterior [34-36]. The anomaly is named “Marsupial” because such a position of vessels is usually observed in most marsupials [36]. Gladstone, McClure, and Huntington were the first to describe the anomaly in a cadaveric dissection in 1929 [34, 37-39]. There are four groups of marsupial IVC [38]:

A - The left CIV passes above the AA bifurcation, whereas the right CIV lies below its right artery counterpart.

B - The left CIV passes above the AA bifurcation, and the right CIV is located anterior to its right artery counterpart.

C - The IVC is located anterior to the AA, and both common iliac veins pass posterior to their arterial counterparts.

The incidence of marsupial IVC is very difficult to calculate. It is believed to be a very rare anomaly. Babu et al. described a case of marsupial IVC, and after a systematic search, they estimated that approximately 20 cases had been described in medical literature by 2014. The authors also concluded that preaortic iliac confluence derived a normal orthotopic IVC with a right-sided position to the AA. [40]. However, Rocha concluded that marsupial IVC could not be as rare as previously thought because authors observed four cases of IVC during a period of two years [41]. Case reports associated with vascular surgery have described most cases of this anomaly [38, 42, 43]. Generally, the anomaly

is asymptotic and unrelated to abnormal venous drainage from the lower venous parts of the body [38].

Tips and tricks

Marsupial inferior vena cava could be injured in all steps of paraaortic lymphadenectomy, but especially during caudal dissection of the aortocaval lymph nodes, as the vein would be the first vessel encountered.

Retrocaval/circumcaval ureter

Prevalence and surgical anatomy

Hochstetter, in 1893, was the first to describe the circumcaval ureter [44-46]. The terms retrocaval/circumcaval ureter are misleading, as the anomaly represents an alteration of IVC rather than a ureteral developmental anomaly [44-47]. Therefore, some authors named the anomaly “preureteral IVC” [44-47]. The estimated incidence is between 0.06–0.17 percent on average [47]. The anomaly is three times more frequent in women than men [44-47]. The circumcaval ureter (CCU) passes posterior to the IVC at the level between L3-L4 vertebrae, then appears between the IVC and AA and continues its normal distal course [44-47]. There are still some debates about the embryological development of the CCU [44-48]. Some authors have stated that the CCU represents an abnormal persistence of right SUV ventral to ureter instead of posteriorly located SUPVs [49]. Conversely, other authors have concluded that the CCU is formed embryologically due to a persistence of the right posterior cardinal vein [45, 48]. In our opinion, the latter theory seems more logical, as the right posterior cardinal vein is located ventrally to the normal orthotopic position of the ureter [48, 50].

In bilateral duplication or left-sided IVC cases, the CCU could be encountered on the left side [51].

There are two types of CCU [44-51]:

Type I – the ureter passes posterior to the IVC at the third lumbar vertebra level and is J-shaped at the point of obstruction. It is more common than type II.

Type II – The ureter passes posterior to the IVC at a more cranial position than the type I – at the level of the renal pelvis.

Unlike other IVC variations, the CCU is associated with symptoms in the third or

fourth decade of life. Symptoms result from hydronephrosis as the IVC and the psoas major muscle compress the ureter. Multi-slice computed tomography is a preferable imaging modality for evaluating the cause of hydronephrosis. Asymptomatic patients with this anomaly do not require surgical treatment [44-51].

Tips and tricks

Surgeons should be aware of the possibility of CCU in cases of patients with hydronephrosis without clear pathological reasons for its occurrence. Moreover, the CCU is often associated with other anomalies - situs inversus, imperforate anus, esophageal atresia, myelomeningocele, other renal anomalies, etc. [52]. Imaging modalities should diagnose the CCU preoperatively. However, as there is also a chance of false-negative results, surgeons should always be aware of the CCU during retroperitoneal surgery.

Congenital absence of the IVC

Prevalence and surgical anatomy

Congenital absence of the IVC is an extremely rare anomaly, which is often associated with the occurrence of lower-extremity venous insufficiency or idiopathic deep venous thrombosis in young patients (< 30 years of age) [8, 53-56]. The blood passes from the iliac vessels to the lumbar veins, which drain into the azygos-hemiazygos veins more cranially [44]. This rare variation leads to an inadequate deep collateral

venous circulation and the development of lower extremity chronic venous hypertension, thus facilitating deep venous thrombosis [54]. Other anomalies, such as dextrocardia, polysplenia, atrioventricular canal, or asplenia, could also be observed. Additionally, the most frequently observed anomalies related to the absence of the vein are the renal anomalies – right renal aplasia [53-56]. Some authors even termed that combination of variations as “KILT” (kidney and IVC anomalies and leg thrombosis) [44, 57].

The reasons for the anomaly are still debatable. Some authors suggest that the absence results from intrauterine or perinatal thrombosis, whereas others believe that the origin is embryonic dysontogenesis - misdevelopment of the right SUPV [44, 55, 58-60]. CT and magnetic resonance imaging (MRI) are the preferable imaging methods to visualize this pathology [55].

Jil et al. divided the absence of the IVC into three groups and described their embryonic etiology [8, 55]:

Lack of the suprarenal part of the IVC – misdevelopment of the right SUV vein. The venous blood from the infrarenal portion of the IVC drain into the heart through the azygos and hemiazygos veins

Absence of the infrarenal portion of the IVC – misdevelopment of the right SUPV and posterior cardinal vein

Complete absence – misdevelopment of all three embryogenic veins

Table 1. Anatomical variations and embryogenic etiology of the IVC

Variation of the IVC	Embryonic etiology
Left IVC	Persistence of left SUPV with regression of its right counterpart
Ipsilateral duplication of the IVC	Right – persistence of right SUV/SUPVs. Left- regression of right SUV/SUPVs and persistence of its left counterpart
Bilateral duplication of the IVC	Persistence of left and right SUPVs
Left IVC with regressed right IVC	Persistence of the left SUPV with partial regression of right SUPV
Marsupial IVC	Persistence of the superior compartment of the embryologic circumaortic venous ring with regression of the posterior compartment of the ring
Congenital absence of the IVC	Misdevelopment of the venous system during embryogenesis or intrauterine/perinatal thrombosis
Absence of the suprarenal portion of the IVC	Misdevelopment of the right SUV
Absence of the infrarenal portion of the IVC	Misdevelopment of the right SUPV and right posterior cardinal vein
Complete absence	Misdevelopment of all embryogenic veins
Retrocaval/circumcaval ureter	Persistence of right posterior cardinal vein

Tips and tricks

Oncogynecologists should predict the possibility of congenital absence of the IVC in cases with idiopathic deep venous thrombosis or cardiac or vascular anomalies. The absence of the IVC is dangerous during retroperitoneal surgery, as collateral vessels could be injured during dissection. The collaterals could be misdiagnosed on CT or other imaging modalities with enlarged PALNs or paraspinal masses [61, 62].

Variations of the IVC and its embryogenic etiology are summarized in Table 1.

Conclusion

Detailed knowledge of anatomical variations' embryonic aspects is mandatory to understand their occurrence better. Variations of the IVC are rare, but they are related to an increased risk of vascular injury during procedures in the retroperitoneum in gynecologic oncology.

Variations of the IVC are often associated with other cardiovascular or renal anomalies. Often, radiologists do not consider or pay less attention to the presence of possible variations in the retroperitoneum. Moreover, oncogynecologists should be familiar with IVC anomalies even if they are not confirmed preoperatively due to the possible imaging negative results.

References

1. Gray H, Standring S, Harold Ellis H, Berkovitz B. Gray's Anatomy: The Anatomical Basis of Clinical Practice, 39th ed. New York, USA; Elsevier Churchill Livingstone Edinburgh: 2005. p. 2171-5.
2. Ang WC, Doyle T, Stringer MD. Left-sided and duplicate inferior vena cava: a case series and review. *Clin Anat*. 2013;26(8):990-1001.
3. Xue HG, Yang CY, Asakawa M, Tanuma K, Ozawa H. Duplication of the inferior vena cava associated with other variations. *Anat Sci Int*. 2007;82(2):121-5. Erratum in: *Anat Sci Int*. 2007 Sep;82(3):186.
4. Giordano JM, Trout HH. Anomalies of the inferior vena cava. *J Vasc Surg*. 1986;3(6):924-8.
5. Li SJ, Lee J, Hall J, Sutherland TR. The inferior vena cava: anatomical variants and acquired pathologies. *Insights Imaging*. 2021;12(1):123.
6. Shin DS, Sandstrom CK, Ingraham CR, Monroe EJ, Johnson GE. The inferior vena cava: a pictorial review of embryology, anatomy, pathology, and interventions. *Abdom Radiol (NY)*. 2019;44(7):2511-27.
7. Malaki M, Willis AP, Jones RG. Congenital anomalies of the inferior vena cava. *Clin Radiol*. 2012;67(2):165-71.
8. Bass JE, Redwine MD, Kramer LA, Huynh PT, Harris JH. Spectrum of Congenital Anomalies of the Inferior Vena Cava: Cross-sectional Imaging Findings. *RadioGraphics*. 2000;20(3):639-52.
9. Natsis K, Apostolidis S, Nousseios G, Papathanasiou E, Kyriazidou A, Vyzas V. Duplication of the inferior vena cava: anatomy, embryology and classification proposal. *Anat Sci Int*. 2009;85(1):56-60.
10. Hostiuc S, Minoiu C, Negoii I, Rusu MC, Hostiuc M. Duplication and transposition of inferior vena cava: A meta-analysis of prevalence. *J Vasc Surg Venous Lymphat Disord*. 2019;7(5):742-55.
11. Rajabnejad Y, Aliakbarian M, Rajabnejad A, Motie MR. Left-Sided Inferior Vena Cava Encountered During Organ Retrieval Surgery: Report of Two Cases. *Int J Organ Transplant Med*. 2016;7(4):229-32.
12. Jiménez Gil R, González Gutierrez MA, Seminario Noguera I, Gaya Alarcón J, Morant Gimeno F. Left-sided Inferior Vena Cava and Aortoiliac Surgery. *EJVES Extra*. 2008;15(2):9-11.
13. Chang S-J, Ryu H-S. Laparoscopic para-aortic lymphadenectomy in endometrial cancer patient with left-sided inferior vena cava. *Gynecol Oncol*. 2012;126(1):147-8.
14. Forster J, Biyani CS, Weston PMT. A gentle reminder in the laparoscopic era left-sided inferior vena cava. *Int Urol Nephrol*. 2006;38(3-4):439-42.
15. Milani C, Constantinou M, Ber D, Butera JN, Colvin GA. Left sided inferior vena cava duplication and venous thromboembolism: case report and review of literature. *J Hematol Oncol*. 2008;24(1).
16. Chee YL, Culligan DJ, Watson HG: Inferior vena cava malformation as a risk factor for deep venous thrombosis in the young. *Br J Haematol*. 2001;114:878-80.
17. Dumitru R, Scarlat A, Ionescu M, Dumitrascu T. Left-sided duplication of inferior vena cava: clinical implications in a patient with sigmoid adenocarcinoma. *The Medical-Surgical Journal*. 2012;116(3):858-61.
18. Tagliafico A, Capaccio E, Rosenberg I, Martinoli C, Derchi LE. Double right inferior vena cava associated with an anomalous venous ring encircling the right common iliac artery: Report of one case with CT and US. *Eur J Radiol Extra*.

- 2007;64(3):111-5.
19. Doyle AJ, Melendez MG, Simons MA. Ipsilateral duplication of the inferior vena cava. *J Clin Ultrasound*. 1992;20(7):481-5.
 20. Mathews R, Smith PA, Fishman EK, Marshall FF. Anomalies of the inferior vena cava and renal veins: embryologic and surgical considerations. *Urology*. 1999;53(5):873-80.
 21. Chen H, Emura S, Nagasaki S, Kubo K. Double inferior vena cava with interiliac vein: A case report and literature review. *Okajimas Folia Anat Jpn*. 2012;88(4):147-51.
 22. Anne N, Pallapothu R, Holmes R, Johnson MD. Inferior Vena Cava Duplication and Deep Venous Thrombosis: Case Report and Review of Literature. *Ann Vasc Surg*. 2005;19(5):740-3.
 23. Tamizifar B, Seilani P, Zadeh MR. Duplication of the inferior vena cava and thrombosis: A rare case. *J Res Med Sci*. 2013;18(10):911-3.
 24. Kouroukis C, Leclerc JR. Pulmonary Embolism with Duplicated Inferior Vena Cava. *Chest*. 1996;109(4):1111-3.
 25. William RR, Fernando RG. Duplication of the Inferior Vena Cava in Thromboembolic Disease. *Chest*. 1986;90(6):916-8.
 26. Shaha P, Garg A, Sahoo K, Kothari N, Garg P. Duplication of inferior vena cava with associated anomalies: a rare case report. *J Clin Diagn Res*. 2016;10(3):TD01-04.
 27. Chou CT, Yang AD, Hong YC, Wu HK. Bilateral retrocaval ureters with IVC duplication. *Abdom Imaging*. 2006;31(5):596-7.
 28. Smith TR, Frost A. Anomalous inferior vena cava associated with horseshoe kidneys. *Clin Imaging*. 1996;20(4):276-8.
 29. Sousa Gomes M, Pardal C, Monteiro C, Serrano P. Double inferior vena cava in gynaecological oncology surgery. *BMJ case reports*. 2020;13(12):e240361.
 30. Sahoo PK, Mohanty RK. Duplication of inferior vena cava in a case of ovarian carcinoma. *J Anat Soc India*. 2014;63:S42-S43.
 31. Loo ZY, Jhummon-Mahadnac N. Double inferior vena cava: a rare but important anatomical variation. *Int J Anat Res*. 2013;1(3):174-7.
 32. Honma S, Tokiyoshi A, Kawai K, Koizumi M, Kodama K. Left inferior vena cava with regressed right inferior vena cava. *Anat Sci Int*. 2008;83(3):173-8.
 33. Taniguchi H, Miyauchi Y, Kobayashi Y, Seino Y, Takano T. Case report: pulmonary embolism from thrombosis in a duplicated inferior vena cava developing after an electrophysiologic procedure. *J Interv Card Electrophysiol*. 2001;5(1):75-9.
 34. Liu J, Ridley L. Classics in abdominal imaging: marsupial cava. *Abdom Radiol*. 2021;46(7):3521-2.
 35. Reis Filho AJS, Rocha MA, Lemos GR, Yamauchi FI, Tachibana A, Baroni RH. Marsupial vena cava mimicking lymph node enlargement on tomography. *Einstein (São Paulo)*. 2018;16(3):eAI4394.
 36. Singh R, Sieunarine K. Marsupial Inferior Vena Cava. *J Vasc Interv Radiol*. 2014;25(1):71.
 37. Gladstone RJ. Development of the Inferior Vena Cava in the Light of Recent Research, with Especial Reference to Certain Abnormalities and Current Descriptions of the Ascending Lumbar and Azygos Veins. *J Anat*. 1929;64(Pt 1):70-93.
 38. Ruemenapf G, Rupprecht H, Schweiger H. Preaortic iliac confluence: a rare anomaly of the inferior vena cava. *J Vasc Surg*. 1998;27(4):767-71.
 39. McClure CFW. The mammalian vena cava posterior: an ontogenetic interpretation of the atypical forms of the vena cava posterior (inferior) found in the adult domestic cat (*Felis domestica*) and in man. *Am Anat Memoirs*. 1929;15:1-55.
 40. Babu CS, Lalwani R & Kumar I. Right Double Inferior Vena Cava (IVC) with Preaortic Iliac Confluence - Case Report and Review of Literature. *J Clin Diagn Res*. 2014;8(2):130-2.
 41. De Souza Rocha M, Lourenço RB, Chang YS, Mello Santiago Gebrim EM, Cerri GG. Preaortic Iliac Confluence (Marsupial Vena Cava). *J Comp Assist Tomogr*. 2008;32(5):706-9.
 42. Kleiner DE, Harthun NL. Unusual Anomaly Complicating Abdominal Aortic Aneurysm Repair: Anterior Inferior Vena Cava. *Vasc Endovasc Surg*. 2008;43(1):87-8.
 43. Schiavetta A, Cerruti R, Cantello C, Patrone P. "Marsupial cava" and ruptured abdominal aortic aneurysm. *J Vasc Surg*. 1998;28(4):719-22.
 44. González J, Gaynor JJ, Albéniz LF, Ciancio G. Inferior Vena Cava System Anomalies: Surgical Implications. *Curr Urol Rep*. 2017;18(2):10.
 45. Ratkal JM, Jadhav R, Naique Dessai RR. Circumcaval Ureter-the Paradigm Shift in Diagnosis and Management. *Indian J Surg*. 2016;78(1):37-40.
 46. Hochstetter F. Contribution to the developmental history of the venous system of the amniotes III. *Sucker Morphology Jahrbücher*. 1893;20:543-8.
 47. Atawurah H, Maison POM, Owusu-Ansah M, Asante-Asamani A. Retrocaval Ureter: Report of Two Cases. *Case Rep Urol*. 2019;ID 281548, 3 p.
 48. Lesma A, Bocciardi A, Rigatti P. Circumcaval Ureter: Embryology. *Eur Urol Suppl*. 2006;5(5):444-8.
 49. Agarwal S, Goel S, Sankhwar S, Garg G.

- Circumcaval ureter/retrocaval ureter. BMJ case reports. 2018:bcr2018225449.
50. Bhattacharjee S, Sanga S, Gupta P, George RA. Retrocaval ureter or preureteral vena cava: Lest we forget this rare cause of hydronephrosis. *Med J Armed Forces India*. 2016;72(Suppl 1):S77-S79.
 51. Rubinstein I, Cavalcanti AG, Canalini AF, Freitas MA, Accioly PM. Left retrocaval ureter associated with inferior vena caval duplication. *J Urol*. 1999;162(4):1373-4.
 52. Perimenis P, Gyftopoulos K, Athanasopoulos A, Pastromas V, Barbaliás G. Retrocaval ureter and associated abnormalities. *Int Urol Nephrol*. 2002;33(1):19-22.
 53. Iqbal J, Nagaraju E. Congenital absence of inferior vena cava and thrombosis: a case report. *J Med Case Rep*. 2008;2:46.
 54. Chew RR, Lim AH, Toh D. Congenital absence of inferior vena cava: an under recognised cause of unprovoked venous thromboembolism. *QJM*. 2018;111(2):117-8.
 55. Gil RJ, Pérez AM, Arias JB, Pascual FB & Romero ES. Agenesis of the inferior vena cava associated with lower extremities and pelvic venous thrombosis. *J Vasc Surg*. 2006;44(5):1114-6.
 56. Gayer G, Zissin R, Strauss S, Hertz M. IVC anomalies and right renal aplasia detected on CT: a possible link? *Abdom Imaging*. 2003;28:395-9.
 57. Van Veen J, Hampton KK & Makris M. Kilt syndrome? *Br J Haematol*. 2002;118(4):1199-200.
 58. Obernosterer M, Aschauer W, Schnedl RW. Lipp Anomalies of the inferior vena cava in patients with iliac venous thrombosis. *Ann Intern Med*. 2002;136:37-41.
 59. Ramanathan T, Hughes MD, Richardson AJ. Perinatal inferior vena cava thrombosis and absence of the infrarenal inferior vena cava. *J Vasc Surg*. 2001;33:1097-9.
 60. Wax JR, Pinette MG, Fife J, Blackstone J, Cartin A. Absent infrarenal inferior vena cava: an unusual cause of pelvic varices. *J Ultrasound Med*. 2007;26:699-701.
 61. Milner LB, Marchan R. Complete absence of the inferior vena cava presenting as a paraspinal mass. *Thorax*. 1980;35:798-800.
 62. Sneed Hamdallah I & Sardi A. Absence of the Retrohepatic Inferior Vena Cava: What the Surgeon Should Know. *Am Surg*. 2005;71(6):502-4.