

BASIC NEURONAVIGATION OPTIONS FOR CORTICAL AND SUBCORTICAL BRAIN LESIONS SURGERY

**Milan N. Mladenovski,
Nikolay V. Vasilev,
Mladen E. Ovcharov,
Iliya V. Valkov**

*Department of Neurology and
Neurosurgery,
Medical University – Pleven,
Bulgaria*

Corresponding Author:
Milan N. Mladenovski
Department of Neurology and
Neurosurgery,
Medical University – Pleven
Bulgaria
1, St. Kl. Ochridski Str.
Pleven, 5800
Bulgaria
e-mail: milanmladenovski@gmail.com

Received: October 04, 2018
Revision received: November 07, 2018
Accepted: January 17, 2019

Summary

Craniometric points are essential for orienting neurosurgeons in their practice. Understanding the correlations of these points help to manage any pathological lesion located on the cortical surface and subcortically. The brain sulci and gyri should be identified before craniotomy. It is difficult to identify these anatomical structures intraoperatively (after craniotomy) with precision. The main purpose of this study was to collect as much information as possible from the literature and our clinical practice in order to facilitate the placement of craniotomies without using modern neuronavigation systems. Operative reports from the last five years on cranial operations for cortical and subcortical lesions were reviewed. All the craniotomies had been planned, using four methods: detection of craniometric points, computed tomography (CT) scans/topograms, magnetic resonance imaging (MRI) scans/topograms, and intraoperative real-time ultrasonography (USG). Retrospectively, we analyzed 295 cranial operations. Our analysis showed that operating on for cortical lesions, we had frequently used the first and the second method mentioned above (118 patients), while in cases of subcortical lesions, we had used craniometric points, MRI scans/topograms and intraoperative real-time USG as methods of neuronavigation (177 patients). These results show that craniometric points are essential in both neurosurgical procedures.

Key words: neuronavigation, craniometric points, modern neuronavigation systems, CT/MRI, topograms, intraoperative real-time ultrasonography (USG)

Introduction

Craniometric points are cranial landmarks from which craniometric measurements can be taken.

Landmarks are anatomical structures used as points of origin in locating other anatomical structures. Craniometric points are essential cranial points that orientate neurosurgeons in practice. The brain sulci and gyri could be identified before craniotomy, and this makes it possible to approach any pathological lesion located on the cortical surface or deep in the brain. Precise identification of these anatomical structures intraoperatively (after craniotomy) is difficult, so the main objective of this study was to collect as much

information as possible from the literature and our clinical practice to facilitate the placement of craniotomies without using modern neuronavigation systems.

In the study, the term “neuronavigation” is not a synonym for image-guided surgery (IGS) and computer-assisted/computer-aided surgery (CAS), the latter two being synonyms for modern neuronavigation systems. Neuronavigation is a technique designed to help neurosurgeons precisely determine the location of various cortical and subcortical lesions by using methods such as craniometric points, computed tomography (CT), magnetic resonance imaging (MRI), ultrasonography (USG) images etc.

Materials and Methods

Operative reports from 2013 to 2018 were reviewed on surgeries performed at the Neurosurgery Clinic, University Multiprofile Hospital for Active Treatment “Dr G. Stranski” in Pleven. Two hundred ninety-five cranial operations for cortical and subcortical tumor lesions were reviewed. All craniotomies had been planned by using four methods: craniometric points, CT scans/topograms, MRI scans/topograms, and intraoperative real-time ultrasonography.

All images were previewed by using RadiAnt DICOM Viewer, designed to use resources as efficiently as possible in viewing medical images.

Basic anthropological (craniometric) points

Some of the essential anthropological points are very useful references for precise description of the approach planned (Table 1). The major advantage comes from their feature – they can be seen both on the head and the imaging studies showing the intracranial pathology found [1-4].

Topography of the main cerebral sulci

The lateral and central fissures are the two most important sulci on the convex surface of the cerebral hemisphere, serving as references for localizing the other sulci and convolutions of the hemispheres. However, when planning craniotomies, displacement produced by mass lesions should be also considered, since, after the planned cortical exposure, gyri and sulci can be found to be not exactly at their expected locations.

According to the simplified Kronlein method, a horizontal line is drawn at the level of the upper orbital edge (Figure 1).

Then two vertical lines are superimposed: the first one through the mid-point of the zygomatic arch, and the second through the posterior border of the auricle. The line connecting the intersection point between the horizontal and the first vertical line with the point, where the second vertical line crosses the midline, corresponds to the projection of the central sulcus. If the angle, formed by the projection of the central sulcus

Table 1. Basic anthropological (craniometric) points and their characteristics

Craniometric points	Characteristics
Nasion	A point situated of the base of the nose, in the middle of the naso-frontal suture
Bregma	A point, where the coronal and sagittal sutures join; on the intact skin it can be determined as the intersection of the two perpendicular lines, drawn up from the mid-points of both zygomatic arches
Lambda	The point, where the lambdoid and sagittal sutures join
Inion	This point corresponds to the external occipital protuberance
Estephanon	Symmetrical points on both sides of the skull at the place, where the coronal suture crosses the superior temporal line
Pterion	Approximately symmetrical points on both sides of the skull, located where the frontal, parietal and temporal bones join the large wing of the sphenoid bone
Asterion	Similar to the previous bilateral points at the place, where the occipital and parietal bones join with the mastoid part of the temporal bone
Glabella (g)	It is a cephalometric landmark that is just superior to the nasion

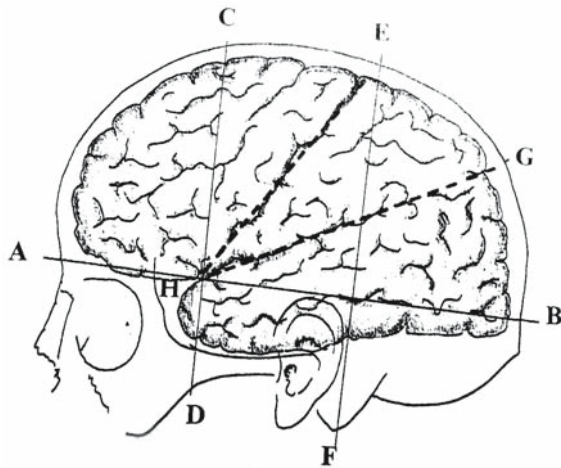


Figure 1. Kronlein method

*A-B horizontal line at the level of superior orbital edge, C-D first vertical line, E-F second vertical line, H-E projection of the central sulcus, H-G projection of the lateral cerebral sulcus (sulcus of Sylvius).

and the horizontal line is bisected, this latter line will correspond to the lateral sulcus [5, 6].

According to Egorov's method for identification, the central sulcus projection corresponds to the line, which begins 2 cm behind the midpoint of the nasion-inion distance on the sagittal line and forms 60 degrees of the angle with it, open in an anterobasal direction. Thus, topography of the two basic fissures of the cerebral hemisphere (the lateral and central sulci) can be determined in the following simple way: the lateral sulcus lies all along the line

connecting the zygomatic process of the frontal bone with a point at 3/4 of the length of the nasion-inion distance, starting from the nasion. The central sulcus corresponds to the upper half of the line, connecting the midline (2cm behind it is the nasion-inion midpoint) and reaches the middle of the zygomatic arch [5, 6].

Correlations between anthropological (craniometric) points are known as craniometric key points [7]. These are points of crucial importance that help to identify the cortical brain sulci and gyri (Table 2).

CT brain scans/topograms

CT head (brain) scan is the most common cranial investigation in neurosurgery. A head CT is as important as a chest x-ray is in internal medicine. A systematic review of CT scans can prevent common errors, e.g. seeing an obvious large parietal metastasis, and missing a smaller one at the posterior cranial fossa in the cerebellum.

We should point out that it is essential to approach this cranial investigation in a systematic fashion in order to bypass any misstep in diagnosis and neuronavigation.

CT scan/topogram is one of the options for neuronavigation. It is absolutely necessary for craniotomies. Neuroradiologists should include CT topograms in every CT head scan (Figures 2-4, 5a-b, 6a-b).

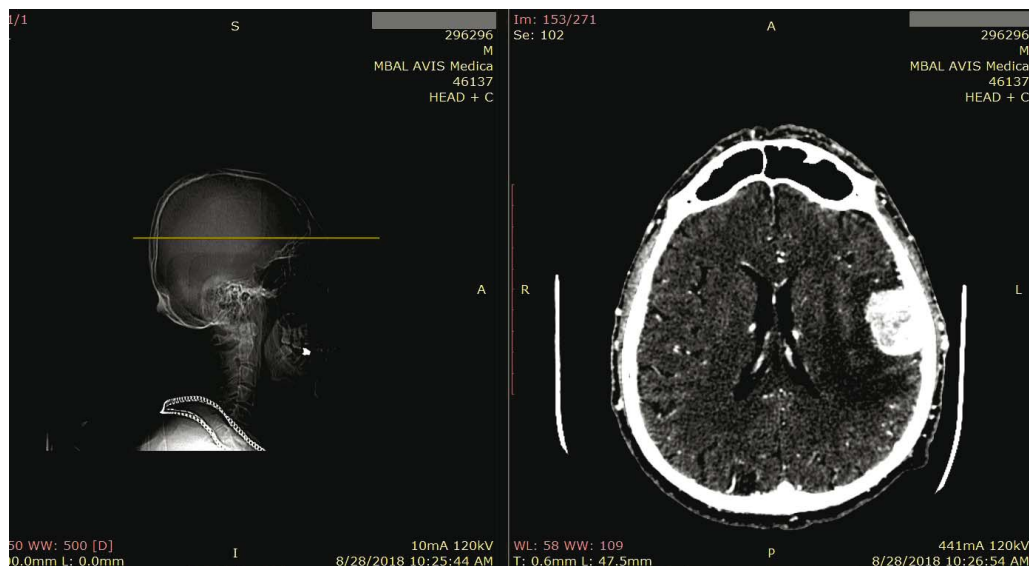


Figure 2. CT topogram

*The tumor (meningioma) is located in the left parieto-temporal region. Just anterior to IRP

Table 2. Craniometric key points

Craniometric key points	Abbreviation
Anterior sylvian point (external cranial surface at the anterior squamosus)	ASP
Sylvian Fissure	SyF
Inferior Rolandic point (approximately 4cm above the tragus)	IRP
Distance between the ASP and the IRP along the SyF is of around 2-2.5 cm (2.3 cm)	ASP/IRP distance
Inferior frontal sulcus and precentral sulcus meeting point lies around 2 cm posterior to the estephanion	IFS/PreCS
Estephanion point is a craniometric point at the level of the intersection between the coronal suture and the superior temporal line	Es
An easy way to determine Broca area on the dominant hemisphere is by localizing the four craniometrical points: the Estephanion; 2 cm posterior to the Estephanion; the anterior Sylvian point; and the IRP	Broca area
Superior frontal sulcus and precentral sulcus meeting point	SFS/PCS
Posterior coronal point – is a craniometrical point located 3 cm lateral to the sagittal suture and 1 cm posterior to the coronal suture; this PCop locates the hand motor cortex	PCop
Superior rolandic point (5 cm posterior to the Bregma)	SRP
Intraparietal and postcentral sulcus meeting point. IPP – intraparietal point (corresponds IPS/PCS). Located 6 cm anterior to Lambda and 5 cm laterally to the sagittal suture	IPS/PCS
External occipital fissure	EOF
External occipital fissure and parieto-occipital sulcus meeting point (3 cm superior to the Opisthocranion (not to be confused with the Inion)	EOF/POS
Eurion (junction of the superior temporal line (STL) and a vertical line drawn over the most posterior part of the mastoid)	Eu
The Euryon was found to be over the superior aspect of the supramarginalis gyrus (SMG). The SMG and Angular Gyrus (AG) belong to the inferior parietal lobule and are separated from the superior parietal lobe by the intraparietal sulcus. Supramarginal gyrus (SMG) is found to be as the most posterior point of Sylvian fissure (SF), while angular gyrus is found to be as the most posterior part of superior temporal sulcus (STS). The sulcus that divides SMG from AG is called the sulcus of Jansen	SMG, AG
Opisthocranon (the most prominent occipital cranial point)	Op
Lambda (sutura lambdoidea – sutura sagitalis meeting point – between 2-4 cm above opisthocranon)	La
Inion – protuberantia occipitalis externa, approximately 2 cm bellow the opisthocranon	In

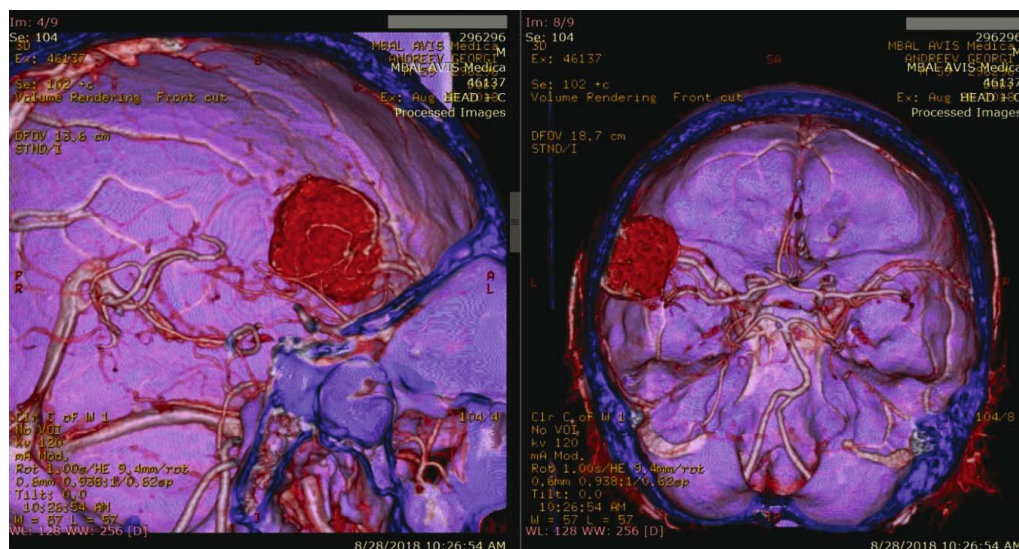


Figure 3. CT angiogram

*Showing the tumor’s vascularization, it is of huge importance for the surgical planning

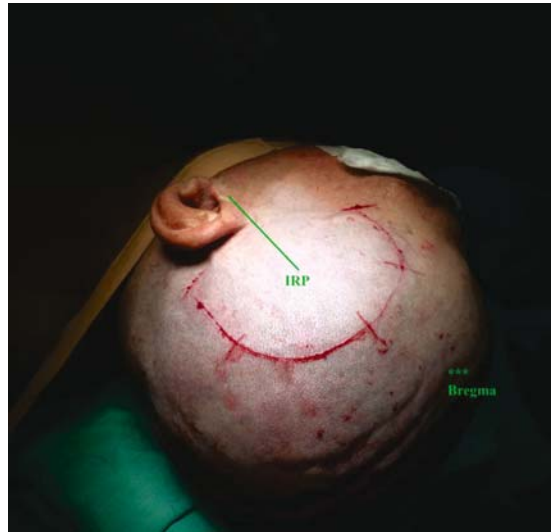

Figure 4. IRP and Bregma as a craniometric points
*CT topogram helps for precise craniotomy

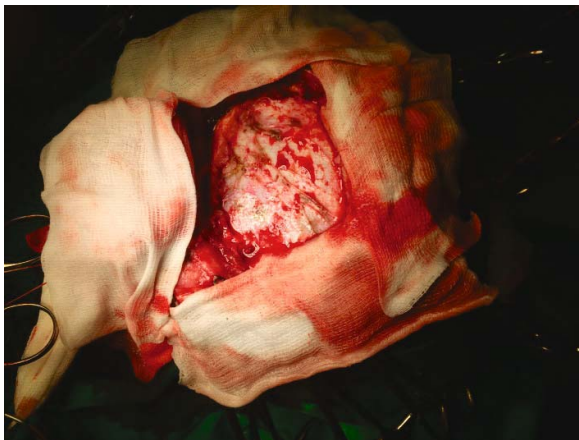


Figure 5a. Bone flap is elevated

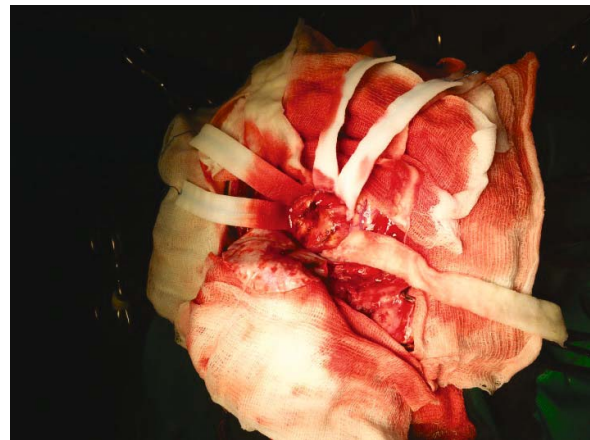


Figure 5b. Dural opening and meningioma is in the center of the trepanation

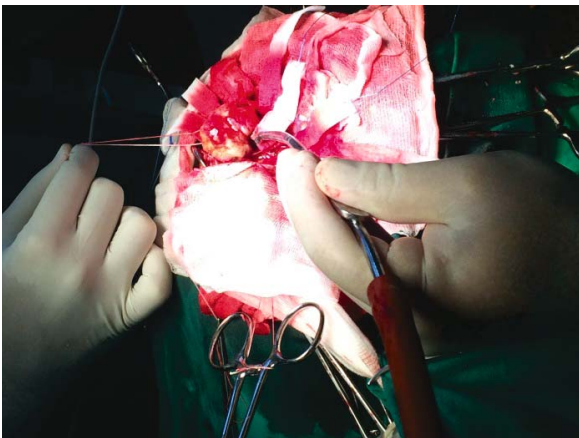


Figure 6a. The tumor is being mobilized

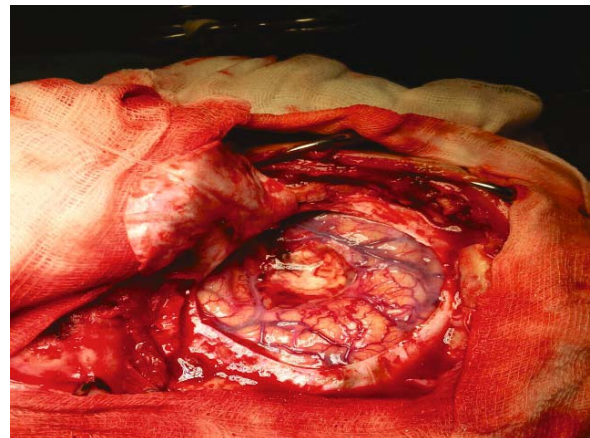


Figure 6b. En block tumor resection

MRI scans/topograms

MRI has recently become a vitally important diagnostic technique. Neurosurgeons often rely on MRI images while planning surgery

for complex cortical or deep pathological lesions and, relatively less often, for diagnostic purposes, since diagnosing using CT scans is less expensive. A relatively large group

of neurosurgeons relies on advanced image guidance technology in their practice. A detailed high-quality neuroradiological investigation, providing reliable information and interpretation on the exact relations of a tumor to adjacent structures and its vascularization is of crucial importance. An MRI scan/topogram as a means of orientation is one of those most commonly used in cases of cortical and subcortical lesions (Figure 7).

Intraoperative real-time ultrasonography

This technique allows determining the exact location of deeply situated intracranial lesions, thus reducing the risk of intraoperative damage to normal tissue and helping to determine the extent of tumor resection. It also reduces the surgery time (Figure 8).

Results

Retrospectively, we analyzed 295 cranial operations for tumor lesions (Table 3).

One hundred sixty-seven patients had been diagnosed via head CT. One hundred twenty-eight patients had been diagnosed by head MRI. Forty-six patients had had CT prior to admission, and MRI investigations were carried out for more precise evaluation. The success rate of the projections used was graded on a scale from one to three (Table 4).

Grade 1: Projections exactly matched the actual tumor (the tumor was in the center of the trepanation).

Grade 2: The margin of error between the projection and the tumor was less than 10mm (the lesion was in external margins of the trepanation but in the surgical field).

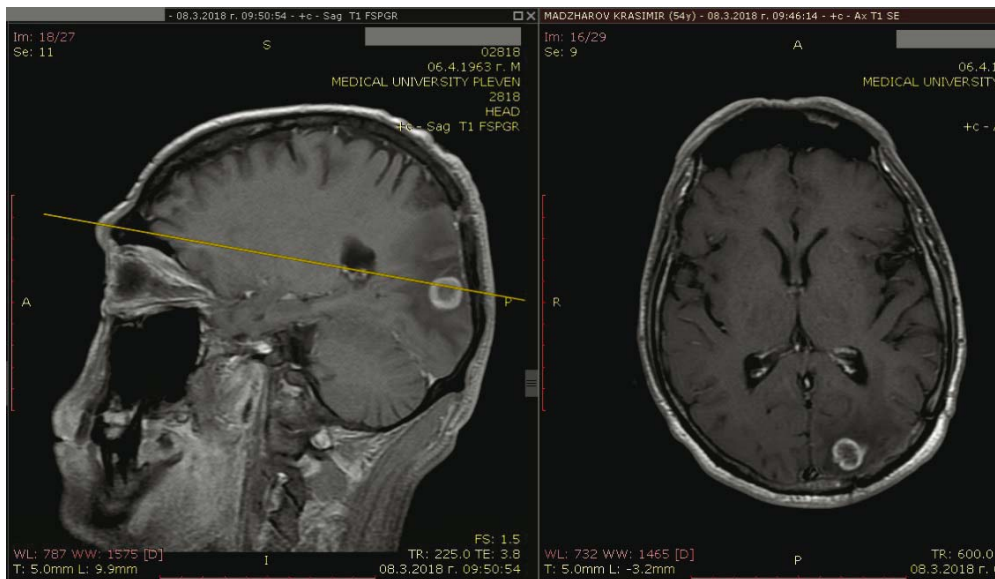


Figure 7. MRI scan/topogram showing occipital meta

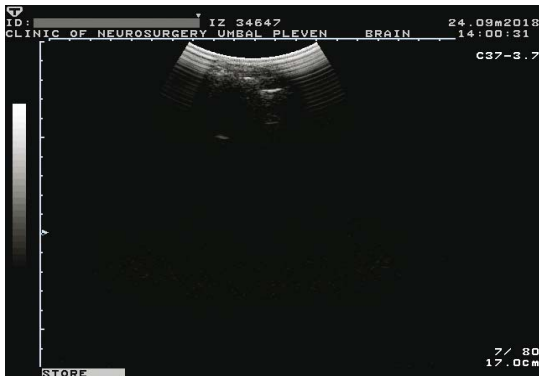

Figure 8. Intraoperative pre-excision USG image
*Note the ovoid lesion.

Table 3. Diagnostic methods used to identify the brain tumor

Patients	Number
CT scan*	167
MRI scan	128
Total	295

*49 CT scanned patients undergo head MRI

Table 4. Grading the success of the projections in the operated patients

Grades	Cortical Tu (n=118)	Subcortical Tu (177)
Grade 1*	94 (79.7%)	96 (54.2%)
Grade 2*	22 (18.6%)	73 (41.2%)
Grade 3	2 (1.7%)	8 (4.6%)

*We consider Grade 1 and Grade 2 as successful

Grade 3: Error greater than 10 mm (the tumor was not in the surgical field, and additional craniotomy was done).

We considered Grade 1 and Grade 2 as successful. Grade 3 projections in a of total 10 patients (3.2%) were due to individual differences in craniometric points and distances, not using real time USG and a surgeon’s emotion and physical fatigue. Our results are based on our practice.

Operating for cortical lesions, we frequently used craniometrical points and CT scans/topograms. These neuronavigation options were used in 118 patients with a success rate of 98.3%.

While operating on for subcortical lesions, we used craniometrical points, MRI scan/topograms and intraoperative real-time USG as methods of neuronavigation in 177 patients with a success rate of 95.4%. Craniometric points proved essential in both operative procedures.

Discussion

Every neurosurgical clinic/medical university wish for a “Brain Theater” – an integrated system of intraoperative MRI, neuronavigation systems, the latest brands of microscopes, video recording and real-time surgeries, all connected with other universities and hospitals. In January 2006, Nagoya University Hospital set up an operating room, which was awarded by the Japan industrial Promotion Organization as the best operating room designed in 2007. In mid- to low economically developed countries such an operating room is still unaffordable.

Proper craniotomy or craniectomy and correct evaluation of the cortical sulci and gyri are the crucial steps for a successful operative procedure. However, their identification could be difficult. To identify these cortical structures, the use of craniometric points is beneficial [8-10]. In our opinion, basic craniometric points such as the sagittal suture, bregma, inion, pterion,

glabella, estephanon are of utmost importance.

The pterion is the most commonly used external landmark in the majority of neurosurgical procedures [10-12]. Therefore, its precise location in relation to other surrounding visible landmarks like the zygomatic arch, frontozygomatic suture, and external acoustic meatus can be very useful for keyhole surgeries in these areas.

Advanced technology has a definitely positive impact on surgical outcome [13-15]. On the one hand, it is an undeniable fact that 3D anatomical knowledge is essential for successful surgical results. On the other hand, when advanced technology is not available or applicable, the importance of 3D anatomical knowledge is beneficial.

The main goal in neurosurgery is to treat neurosurgical pathologies through a minimum tissue dissection, thus allowing for shorter recovery and greater sense of well-being [16]. From our perspective, dissecting through a sulcus is better than dissecting via a gyrus, even enlarging the distance to the tumor (in noneloquent areas).

Although technologic advances offer modern intraoperative guidance tools such as intraoperative magnetic resonance and modern neuronavigation systems, anatomical knowledge remains an essential skill for neurosurgeons when planning and performing neurosurgical procedures, especially in situations in which those guidance systems are unsuitable or unavailable, e.g. in emergency surgery [17, 18]. According to our clinical experience in emergency cranial surgery, a correlation of craniometric points with a CT topogram is absolutely enough.

Craniometric relationships can be used as “internal control” to the application of advanced guidance techniques (neuronavigation, neurophysiological monitoring etc.) [14, 19-22].

Subcortical brain tumors cannot be distinguished from the brain’s surface even after

considerable growth in size. Intraoperative USG and MRI can pinpoint these lesions following cortical exposure, which fact makes them very effective intraoperative diagnostic tools [21, 23, 24].

The main problem of classical neuronavigation is the brainshift [17, 23]. Once the dura is opened, this problem can be solved either by real-time ultrasound or intraoperative MRI, which are not available in many neurosurgical departments. Not surprisingly, modern neuronavigation systems are widely accepted in functional neurosurgery. Moreover, stereotaxic neurosurgery was introduced into practice as a technique in the treatment for functional disorders (psychiatric conditions, pain, movement disorders and epilepsy) [22].

Our Grade 3 results are approximately 3.15%, which makes them comparable to the 2-12% Grade 3 rates reported in the literature [20, 21, 24, 25].

In our opinion, modern neuronavigation systems could be compared with GPS devices, which are so attractive nowadays. Commonly, most of car drivers do not use this tool as long as they are driving in a well-known city or town and they use the same roads day after day. However, if they enter an unfamiliar area, the advantage of this device is remarkably huge as it helps them reach the destination point by using the most proper and secure way.

Conclusions

Classical (basic) neuronavigation is the alpha and omega in neurosurgery. Knowledge of craniometric points and their correlations with CT/MRI is of crucial importance for neurosurgeons, and especially so for the neurosurgery residents. This knowledge could not be replaced by using modern transcranial neuronavigation systems.

Acknowledgements

This article was supported by Project No BG05M2OP001-2.009-0031-C01.

References

1. Lynnerup N, Jacobsen JC. Brief communication: age and fractal dimensions of human sagittal and coronal sutures. *Am J Phys Anthropol.* 2003;121(4):332-6.
2. Madeline LA, Elster AD. Postnatal development of the central skull base: normal variants. *Radiology.* 1995;196(3):757-63.
3. Relethford JH, Harpending HC. Craniometric variation, genetic theory, and modern human origins. *Am J Phys Anthropol.* 1994;95(3):249-70.
4. Furuya Y, Edwards MS, Alpers CE, Tress BM, Ousterhout DK, Norman D. Computerized tomography of cranial sutures. Part 1: Comparison of suture anatomy in children and adults. *J Neurosurg.* 1984;61(1):53-8.
5. Rhoton AL Jr. The Cerebrum. *Anatomy. Neurosurgery.* 2007;61(Suppl 1):37-118.
6. Yasargil MG. *Microneurosurgery, Volume 1: Microsurgical anatomy of the basal cisterns and vessels of the brain, diagnostic studies, general operative techniques. Consideration of the intracranial aneurisms.* New York: Thieme Medical Publishers; 1984.
7. Ribas GC, Yasuda A, Ribas EC, Nishikuni K, Rodrigues AJ Jr: Surgical anatomy of microneurosurgical sulcal key points. *Neurosurgery.* 2006;59(4 Suppl 2):177-210.
8. Wilkinson ID, Romanowski CA, Jellinek DA, Morris J, Griffiths PD. Motor functional MRI for pre-operative and intraoperative neurosurgical guidance. *Br J Radiol.* 2003;76(902):98-103.
9. Coenen VA, Krings T, Axer H, Weidemann J, Kränzlein H, Hans FJ, et al Intraoperative three-dimensional visualization of the pyramidal tract in a neuronavigation system (PTV) reliably predicts true position of principal motor pathways. *Surg Neurol.* 2003;60(5):381-90.
10. Ribas GC, Ribas EC, Rodrigues CJ. The anterior sylvian point and the suprasylvian operculum. *Neurosurg. Focus* 2005;18(6B):E2.
11. Relethford JH. Craniometric variation among modern human populations. *Am J Phys Anthropol.* 1994;95(1):53-62.
12. Yasargil MG, Krisht AF, Ture U, Al-Mefty O, Yasargil DCH. *Microsurgery of insular gliomas: Part IV: Surgical treatment and outcome.* *Contemp Neurosurg.* 2002;24(14):1-8.
13. Yaşargil MG, Türe U, Yaşargil DC. Surgical anatomy of supratentorial midline lesions. *Neurosurg Focus.* 2005;18(6B):E1.
14. Unsgaard G, Rygh OM, Selbekk T, Müller TB, Kolstad F, Lindseth F, et al. Intra-operative 3D ultrasound in neurosurgery. *Acta Neurochir (Wien).* 2006;148(3):235-53.
15. Dohrmann GJ, Rubin JM. History of intraoperative ultrasound in neurosurgery. *Neurosurg Clin N Am.* 2001;12(1):155-66.
16. Reisch R, Stadie A, Kockro RA, Hoof N.

- The keyhole concept in neurosurgery. *World Neurosurg.* 2013;79 (2 Suppl):S17e 9-13.
17. Nimsky C, Ganslandt O, Hastreiter P, Fahlbusch R. Intraoperative compensation for brain shift. *Surg Neurol.* 2001;56(6):357-64.
 18. Gonzales-Portillo G. Localization of the central sulcus. *Surg Neurol.* 1996;46(1):97-9.
 19. Bittar RG, Olivier A, Sadikot AF, Andermann F, Pike GB, Reutens DC. Presurgical motor and somatosensory cortex mapping with functional magnetic resonance imaging and positron emission tomography. *J Neurosurg.* 1999;91(6):915-21.
 20. Taylor DM, Bernstein M. Awake craniotomy with brain mapping as the routine surgical approach to treating patients with supratentorial intraxial tumors: a prospective trial of 200 cases. *J Neurosurg.* 1999;90(1):35-41.
 21. Roselli R, Iacoangeli M, Pentimalli L, Prezioso A, Scerrati M, Rossi GF. Intraoperative real-time ultrasonography in the microsurgical removal of subcortical or deep-seated brain tumors. *Acta Chir Belg.* 1993;93(4):185-7.
 22. Nimsky C, Ganslandt O, Kober H, Buchfelder M, Fahlbusch R: Intraoperative magnetic resonance imaging combined with neuronavigation: a new concept. *Neurosurgery.* 2001;48(5):1089-91.
 23. Tanriover N, Rhoton AL, Kawashima M, Ulm AJ, Yasuda A. Microsurgical anatomy of the insula and the Sylvian fissure. *J Neurosurg.* 2004;100(5):891-922.
 24. Willems PW, van der Sprenkel JW, Tulleken CA, Viergever MA, Taphoorn MJ. Neuronavigation and surgery of intracerebral tumours. *J Neurol.* 2006;253(9):1123-36.
 25. Aydin K, Kocabicak E, Altun A, Ozaydin I, Yazar E, Cokluk C. Use of topical landmarks for percutaneous projection of intracranial tumors for neurosurgical oncology. *Turk Neurosurg.* 2012;22(3):280-5.