

**INCISIONAL ENDOMETRIOSIS: FOUR CLINICAL CASES**

**Tihomir P. Totev,**  
**Grigor A. Gorchev<sup>1</sup>,**  
**Slavcho T. Tomov<sup>2</sup>,**  
**Ina D. Filipova,**  
**Nadezhda H. Hinkova<sup>2</sup>**

*Gynecology Department,  
St. Marina Hospital,  
Pleven, Bulgaria*

<sup>1</sup>*Institute for Scientific Research,  
Medical University – Pleven,  
Bulgaria*

<sup>2</sup>*Department of Midwifery,  
Medical University – Pleven,  
Bulgaria*

**Corresponding Author:**

Tihomir P. Totev  
St. Marina Hospital  
Bulgarska aviatsia Str.  
Pleven, 5800  
Bulgaria  
e-mail: t.totev@mail.bg

**Received:** May 11, 2017

**Revision received:** June 01, 2017

**Accepted:** November 02, 2017

**Summary**

The presence of functioning endometrial glands and stroma outside the uterine cavity is defined as endometriosis. Its incidence is approximately 10-15% of women of fertile age. Incisional endometriosis following obstetric or gynecologic surgery is reported in 0.03-1.08% of women. Most of the cases reported in the literature are related to caesarean section and have required a differential diagnosis with a hernia, abscess, granuloma or lipoma. The diagnosis is based on histological findings. We describe incisional endometriosis in four patients operated on at St. Marina Hospital – Pleven for one year.

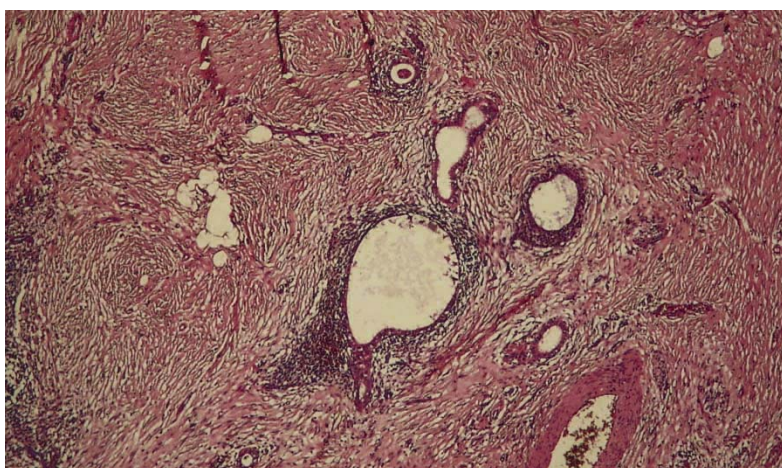
**Key words:** endometriosis, incisional endometriosis

**Introduction**

Endometriosis is a benign gynecologic condition, in which endometrial glands and stroma are found outside the uterus. Worldwide, endometriosis is diagnosed in about 10% (89 million) of women of fertile age [1, 2]. Most often, the pelvic peritoneum, ovaries, ovarian tubes and the uterine body are involved. Endometrial lesions can also be found along the rectovaginal septum, ureters, and the urinary bladder. Endometriosis at the site of incision is a rare extragenital location, seen in 0.03-1.08% of patients after obstetric or gynecologic surgery [3-5]. The onset of endometriosis can be explained by several theories: dysontogenetic (ectopic Mueller's epithelium growth), transplantational (regurgitation of viable endometrial cells and their translocation on the peritoneal mesothelium), metastatic (metastasizing from the uterine cavity by lymphatic or blood vessel route), metaplastic theory (metaplasia of the coelomic epithelium into the endometrial epithelium under the influence of estrogenic hormones) [6-8]. Endometriosis associated with the surgical cicatrix is explained by the transplantational and metastatic theory. The factors responsible for implantation and growth of the endometrial lesions can be divided into anatomical, immunological, genetic and hormonal. Locally, immunologic dysfunction in endometriosis is associated with higher concentration of activated macrophages and proinflammatory and growth cytokines – IL-1, 6,

10, TNF- $\alpha$ , VEGF, reduced cellular immunity and a suppressed function of natural killer cells [9-12]. The genetic factors contributing to the development of endometriosis include altered expression of genes for thrombospondin 1 (THBS1), caldesmon 1 (CALD1), and for cholinergic muscarine receptor 3 (CHRM3). This alteration results in changes in cell function, cellular adhesion and signal transduction [13-15]. The hormonal factors are connected with estrogen-induced endometrial proliferation, as well as higher expression of receptors, and higher sensitivity to estrogens of the ectopic lesions [16]. Anatomical factors are associated with conditions that favor implantation and growth of

viable endometrial cells, including impairment of anatomic integrity during surgery. Incisional endometriosis is a rare clinical phenomenon that is seen after cesarean section, episiotomy, and surgical treatment of the uterine body, ovaries or ovarian tubes [17-19]. Symptoms of endometriosis include a painful nodule on the site of incision, a hemorrhagic lesion on the scar, and changes in the size of the formation during menstrual cycles. The differential diagnosis of incisional endometriosis includes metastases, desmoid tumor, lipoma, sarcoma, fasciitis, fat necrosis, hematoma or abscess. The diagnosis is made following incision and pathohistological analysis of the sample collected (Figure 1).



**Figure 1.** Soft tissues (adipose and fibrous) with benign endometrial glands, surrounded by endometrial stroma. Hematoxylin-eosin staining x10

## **Case Presentation**

### ***Clinical case 1***

A 39-year-old patient was referred for surgical treatment because of a livid formation in an old surgical scar due to midline laparotomy, enlarging during a menstrual cycle. The previous history included one pregnancy, one birth, two abdominal operations – cesarean section (2005) and laparomyomectomy (2009). The somatic status and clinical and laboratory investigations revealed no abnormalities. The patient underwent excision of the endometrial abdominal wall. Intraoperatively, a solid tumor sized 3x3 cm, involving the subcutaneous layer and fascia was palpated in the lower third part of the surgical cicatrix. Pathohistological investigations revealed soft tissues with endometriosis and a granulomatous foreign body.

### ***Clinical case 2***

A 34-year-old patient presented with a palpable formation in the region of a surgical cicatrix. The previous history included two pregnancies and two births, two abdominal operations – cesarean section (2011) and right ovary cystectomy because of endometriosis (2014). Somatic and gynecological status, and clinical and laboratory investigations were normal. A solid tumor, involving the skin and sized 2x2 cm was palpable in the region of the surgical incision after Pfannenstiel incision. Excision of the tumor was performed. Microscopic examination proved endometriosis of the skin and soft subcutaneous tissues.

### ***Clinical case 3***

A 40-year-old patient complained of a painful formation in the cicatrix from a previous cesarean section. The previous history included

two pregnancies, two births, two abdominal operations – cesarean sections in 2004 and 2009. She was in good general health, and results from clinical and laboratory investigations were normal. In the region of the scar (Pfannenstiel incision), a solid tumor sized 4x4 cm and involving the skin, subcutaneous layers, the fascia and muscle tissue was found. Excision of the endometrioma from the cicatrix in the abdominal wall was performed. Histological analysis revealed soft tissue endometriosis.

#### **Clinical case 4**

A 28-year-old patient was referred for treatment because of a mildly painful formation in the

umbilical region. Umbilical hernia was suspected. Her previous history included one pregnancy, one birth, and one abdominal operation – a cesarean section in 2005. Her somatic and gynecological status was normal and clinical and laboratory investigations revealed no abnormalities. A solid tumor sized 1x1 cm was palpated in the umbilical region, involving the subcutaneous layer and the fascia. The tumor was excised, and plastic surgery of the abdominal wall was performed. Histologic investigations revealed hyalinized connective tissue, with embedded endometrial glands, containing scarce endometrial stroma.

The data is presented in Table 1.

**Table 1.** Incisional endometriosis

<b>№</b>	<b>Age</b>	<b>Previous surgery</b>	<b>Parity</b>	<b>Symptoms 1. tumor formation 2. lesion 3. pain</b>	<b>Time to onset of symptoms (months)</b>	<b>Size of formation (cm)</b>	<b>Involvement of tissue structures</b>
1	39	laparomyomectomy; cesarean section	1	2	96	3	skin, subcutaneous layer, fascia
2	34	cesarean section; ovarian cystectomy because of endometriosis	2	1	12	2	skin, subcutaneous layer
3	40	cesarean section	2	1, 3	84	4	skin, subcutaneous layer, fascia, muscle tissue
4	28	cesarean section	1	3	12	1	skin, subcutaneous layer, fascia

#### **Discussion**

The mean age of the patients in the studied group was 35.2 years. In 100% of the cases (n=4), endometriosis occurred following cesarean section. One of the patients had also had another laparotomy for leiomyoma. The most common symptom seen was a formation in the incisional scar, sizing up to 4 cm. The mean duration of the period before onset of symptoms was 51 months. Pelvic endometriosis and incisional endometriosis was established in one of the cases. One typical feature of incisional endometriosis is its occurrence on cicatric tissue, where anatomic layers of the abdominal wall have been damaged. This suggests forming a tissue defect at the expense of the fascia when the formation is removed. Surgical treatment includes wide

incision with sufficient safety margins and patch grafting of the fascial defect with own tissues or a synthetic material, e.g. a polypropylene mesh. Prevention of incisional endometriosis suggests limiting the chances of implantation on the anterior abdominal wall. This can be achieved by adequate trimming of the operative field and applying muscle-to-muscle and muscle-to-serosa suturing techniques to the uterine wall after cesarean section. Using a total suture should be avoided.

#### **Conclusions**

Tumor growths in the surgical cicatrix in women of fertile age are suspicious for endometriomas. Treatment is surgical and includes removal of the lesion and a safety margin. It necessitates

prevention of iatrogenic causes, since incisional endometriosis is most often related to translocation of endometrial tissue during surgical procedures.

## References

1. [Rathod S, Samal SK, Ghose S. Caesarean section scar endometriosis: a case report and review of literature. Int J Reprod Contracept Obstet Gynecol. 2014;3:757-9.](#)
2. Tsenov D, Mainkhard K. [Endometriosis in the surgical scar from caesarean section]. *Akusherstvo Ginekologia (Sofia)*. 2000;39:50-1. Bulgarian.
3. Veda P, Srinivasaiah M. Incisional endometriosis: Diagnosed by fine needle aspiration cytology. *J Lab Physicians*. 2010;2:117-20.
4. Minaglia S, Mishell DR, Ballard CA. Incisional endometriomas after cesarean section: a case series. *J Reprod Med Obstet Gynecol*. 2007;52:630-4.
5. Akbulut S, Sevinc MM, Bakir S, Cakabay B, Sezgin A. Scar endometriosis in the abdominal wall: a predictable condition for experienced surgeons. *Acta Chir Belg*. 2010;110(3):303-7.
6. Sourial S, Tempest N, Hapangama DK. [Theories on the pathogenesis of endometriosis. Int J Reprod Med. 2014;2014:179515. doi:10.1155/2014/179515.](#)
7. Dmowski W, Radwanska E. [Current concepts on pathology, histogenesis and etiology of endometriosis. Acta Obstet Gynecol Scand. 1984;63\(123\):29-33.](#)
8. Gruenwald P. [Origin of endometriosis from the mesenchyme of the celomic walls. Am J Obstet Gynecol. 1942;44\(3\):470-4.](#)
9. Ulukus M. Immunology of endometriosis. *Minerva Ginecol*. 2005;57(3):237-48.
10. [Berkkanoglu M, Arici A. Immunology and endometriosis. Am J Reprod Immunol. 2003;50:48-59.](#)
11. [Sikora J, Mielczarek-Palacz A, Kondera-Anasz Z. Role of Natural Killer cell activity in the pathogenesis of endometriosis. Curr Med Chem. 2011;18\(2\):200-8.](#)
12. Osuga Y. [Lymphocytes in endometriosis. Am J Reprod Immunol. 2011;65\(1\):1-10.](#)
13. [Hansen KA, Eyster KM. Genetics and genomics of endometriosis. Clin Obstet Gynecol. 2010;53:403-12.](#)
14. Koninckx PR, Barlow D, Kennedy S. [Implantation versus infiltration: the sampson versus the endometriotic disease theory. Gynecol Obstet Invest. 1999;47\(1\):3-10.](#)
15. Gilabert-Estelles J, Ramon LA, Gilabert J, Castello R, Estelles A. Expression of the fibrinolytic components in endometriosis. *Pathophysiol Haemost Thromb*. 2006;35(1-2):136-40.
16. Parente C, Bentes De Souza AM, Bianco B, Christofolini DM. The effect of hormones on endometriosis development. *Minerva Ginecol*. 2011;63(4):375-86.
17. [Mistrangelo M, Gilbo N, Cassoni P, Micalef S, Faletti R, Miglietta C, et al. Surgical scar endometriosis. Surg Today. 2014;44:767-72.](#)
18. Horton JD, Dezee KJ, Ahnfeldt EP, Wagner M. Abdominal wall endometriosis: a surgeon's perspective and review of 445 cases. *Am J Surg*. 2008;196:207-12.
19. Nanda JP, Vijay K, Anita G. Scar endometriosis-a sequel of Caesarean section. *J Clin Diagn Res*. 2014;8:9-10.